SCUOLA DERMATOLOGICA
SERGIO CHIMENTI

Roma,
1-2 Dicembre 2023

YES or NO CONTEST 3° INCONTRO
Dermatology Update

Dermoscopia-ritorno alle origini

Alessandro Di Stefani

U.O. di Dermatologia
Università Cattolica del Sacro Cuore, Roma
Fondazione Policlinico Universitario A. Gemelli, IRCCS

SCUOLA DERMATOLOGICA
SERGIO CHIMENTI

SCUOLA DERMATOLOGICA
SERGIO CHIMENTI

Roma,
1-2 Dicembre 2023

YES or NO CONTEST 3° INCONTRO
Dermatology Update

Lesioni Rosa

Alessandro Di Stefani

U.O. di Dermatologia
Università Cattolica del Sacro Cuore, Roma
Fondazione Policlinico Universitario A. Gemelli, IRCCS

SCUOLA DERMATOLOGICA
SERGIO CHIMENTI

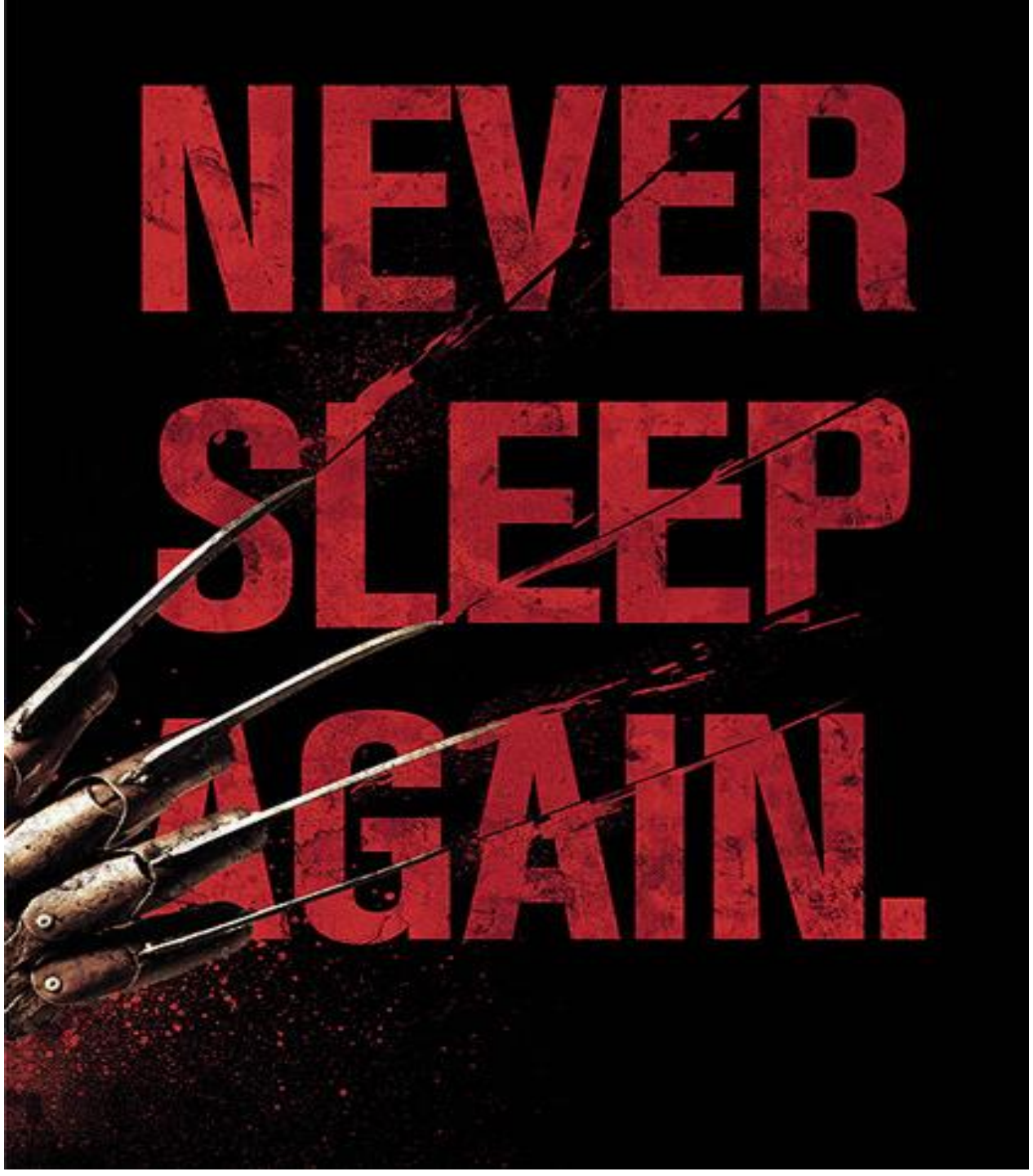
NEVER
SLEEP
AGAIN.


HE KNOWS WHERE YOU SLEEP.
A NIGHTMARE
ON ELM STREET

Australasian Journal of Dermatology

PROFESSIONAL DEVELOPMENT PROGRAM

The most common challenges in melanoma diagnosis and how to avoid them

Ashfaq A Marghoob,[1] Lily Changchien,[1] Jennifer DeFazio,[1] Whitney C Dessio,[2] Josep Malvehy,[3] Iris Zalaudek,[4] Allan C Halpern[1] and Alon Scope[1]

One of the common scenario:

- *Misdiagnosis of nodular melanoma as a benign lesion by the dermatologist*
- *…amelanotic lesions, which are more challenging…*

Australasian Journal of Dermatology (2009) 50, 1–15

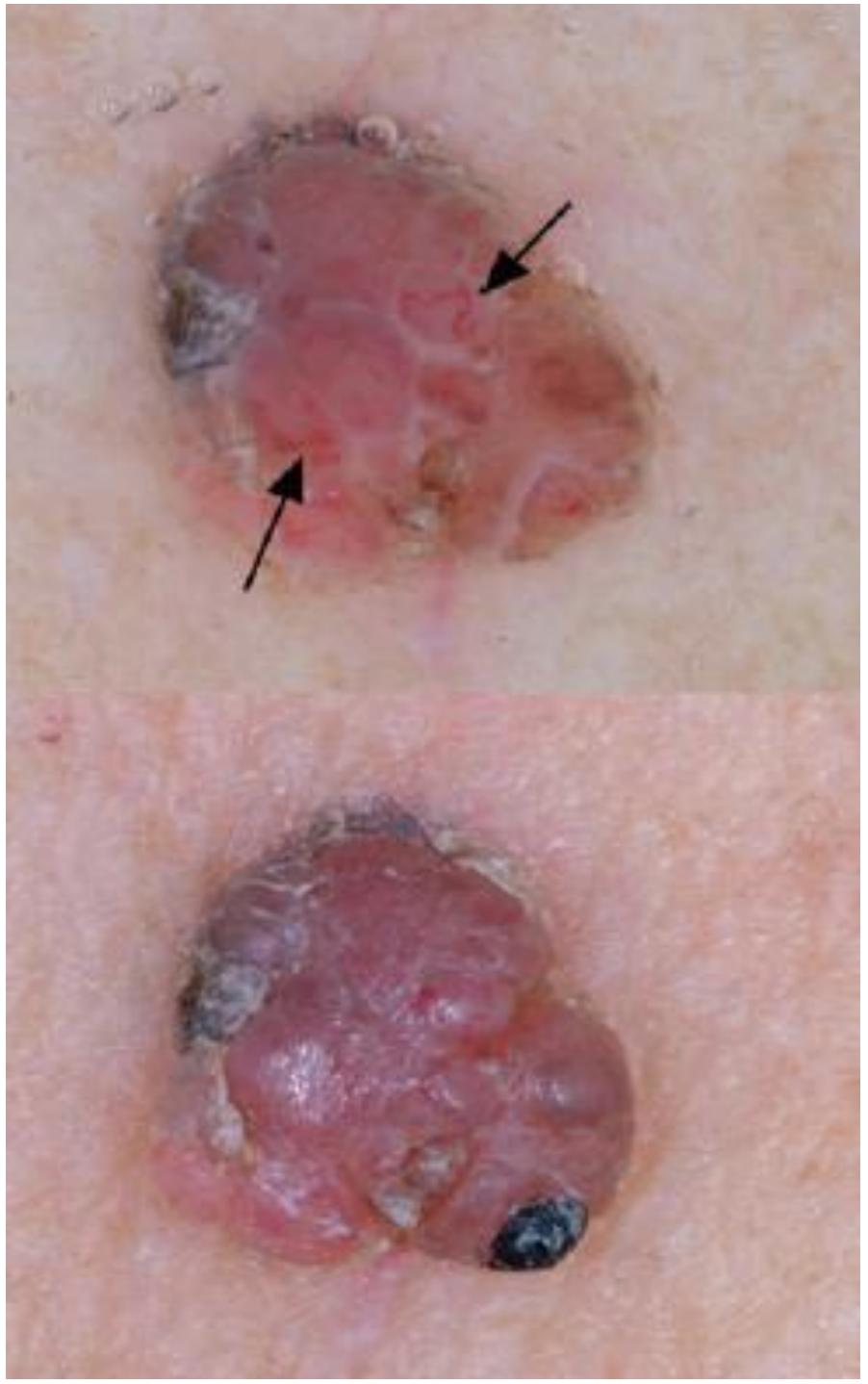

Amelanotic melanoma: The great masquerader

- Amelanotic melanoma accounts for 2-8% of all melanomas
- the real incidence is difficult to estimate due to misdiagnosis
- clinical recognition is particularly difficult, since it might mimic several benign hypo-/non- pigmented skin lesions
- often resulting in a significant delay in diagnosis and deterioration of prognosis

(J Am Acad Dermatol 2000;42:731-4.)

Pink / featureless lesions

- Since the vast majority of melanoma-associated dermoscopic structures are pigmented,

- amelanotic melanoma is usually dermoscopically “**featureless**” and thus difficult to recognize

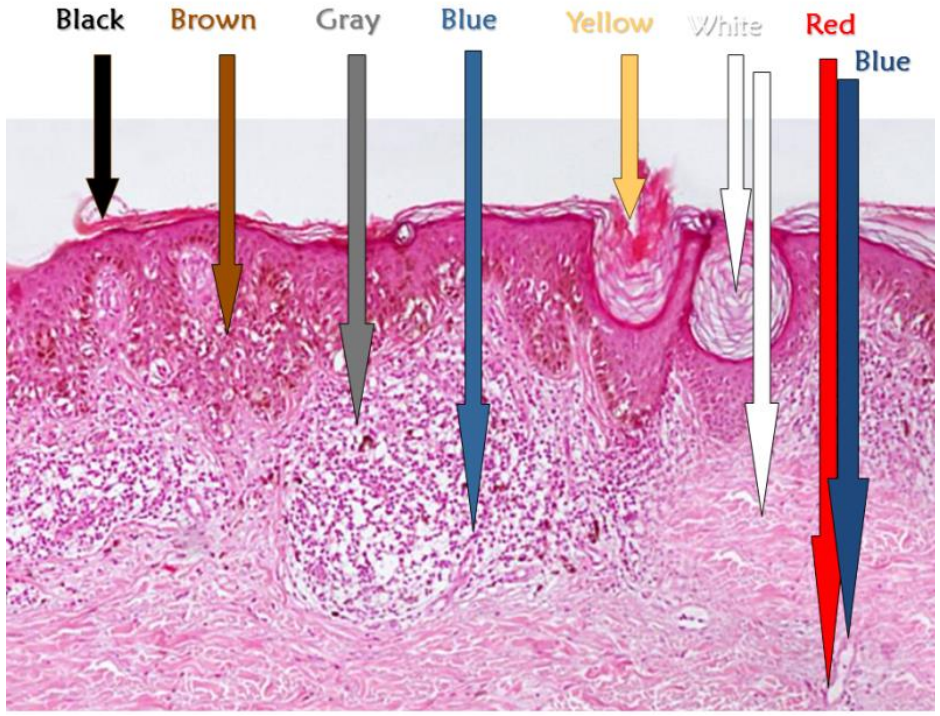

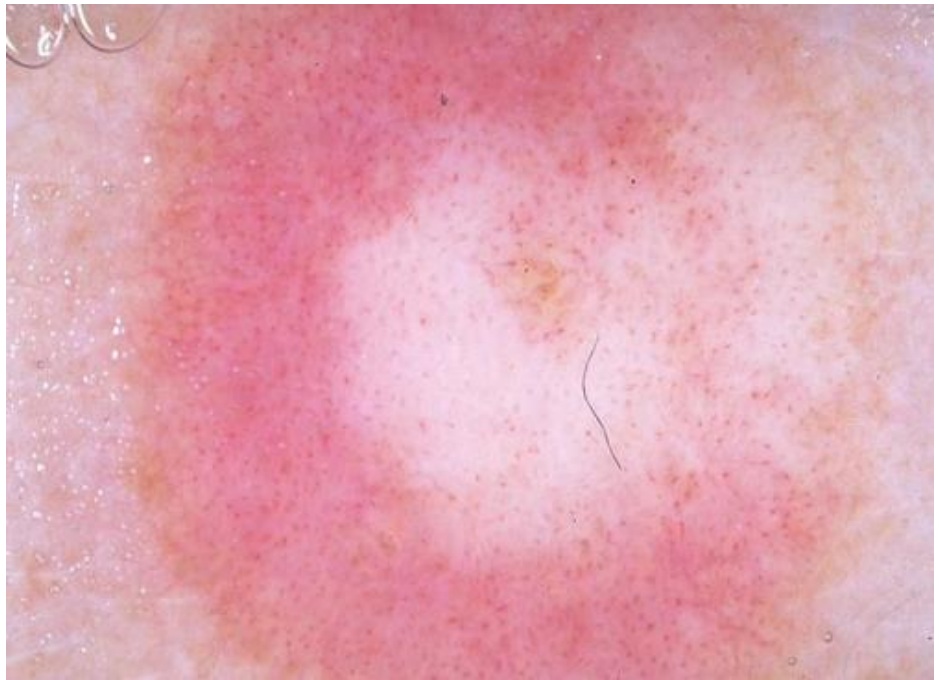

Pink / featureless lesions

- Diminuzione dell’accuratezza diagnostica

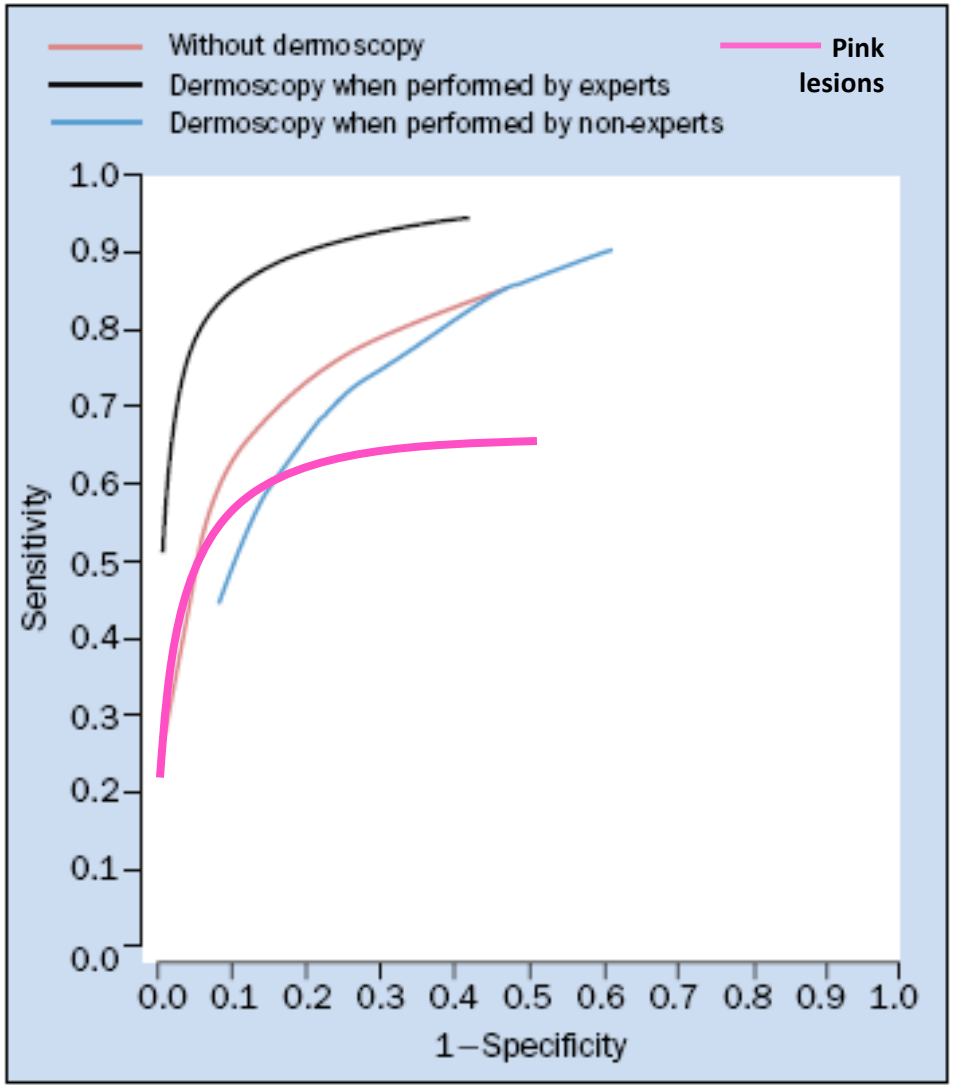

Clinically and dermoscopically featureless melanoma: When prevention fails

Paolo Carli, MD,[a] Daniela Massi, MD,[b] Vincenzo de Giorgi, MD,[a] and Benvenuto Giannotti, MD[a]

- lesions that frequently do not look like melanoma, but mimic a variety of other malignant or benign lesions
- what to do when the lesion is not recognized as suspect?
- Systematic study of clinical and dermoscopic characteristics of false-negative melanoma cases

Featureless

FALSE - NEGATIVE

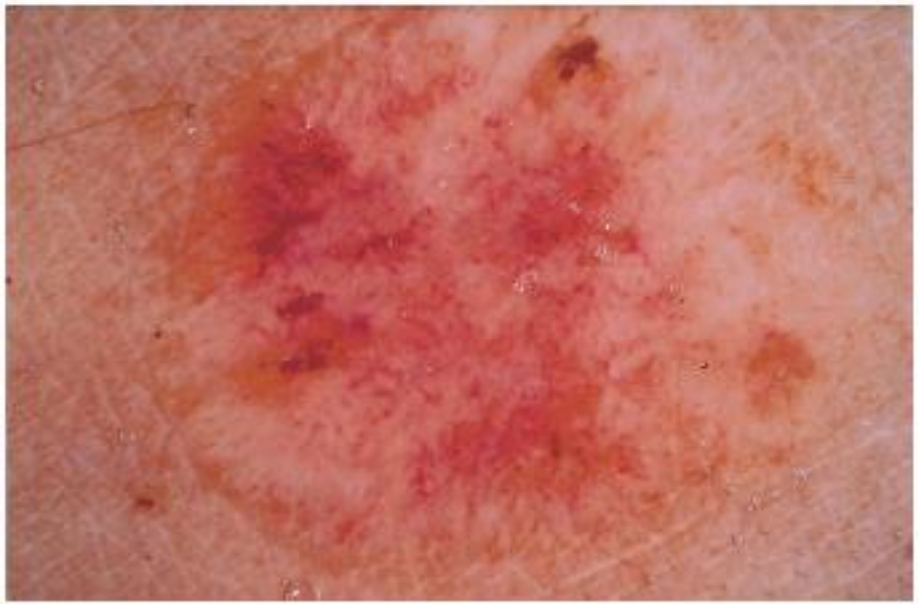

Pink / featureless lesions

1. *Pattern Vascolari*

Vascular Patterns

Vascular Patterns in Skin Tumors

JUERGEN F. KREUSCH, PhD, MD

Clinics in Dermatology • 2002;20:248–254

Dermoscopic analysis of skin tumors in the past has mainly focused on pigmented structures. Features of vascularization received surprisingly little interest, although in the clinical diagnosis, one of the clues for basal-cell carcinoma (BCC) is the visible presence of blood vessels (telangiectasia). Findings in blood vessels yield additional information for the diagnosis of poorly pigmented tumors. Frequently, these lesions are difficult to diagnose due to lack of features from pigmented structures. Only in the early years of skin microscopy did blood vessels receive great attention.[1] In those days, however, interest focused on their value for diagnosing psychiatric and internal diseases rather than skin tumors. This article gives an

Actas Dermosifiliogr. 2012;103(5):357–375

ELSEVIER DOYMA

ACTAS Dermo-Sifiliográficas

Full English text available at www.elsevier.es/ad

REVIEW

Vascular Patterns in Dermoscopy☆

J.M. Martín,[a,*] R. Bella-Navarro,[a] E. Jordá[a,b]

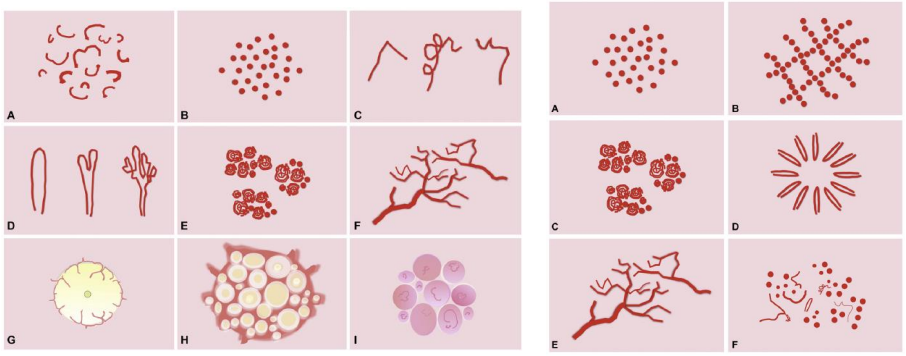

STUDY

Vascular Structures in Skin Tumors

A Dermoscopy Study

Arch Dermatol. 2004;140:1485-1489

Giuseppe Argenziano, MD; Iris Zalaudek, MD; Rosamaria Corona, DSc, M
Francesco Sera, DStat; Lorenza Cicale, MD; Gianluca Petrillo, MD; Eleonora Ruocco, MD;
Rainer Hofmann-Wellenhof, MD; H. Peter Soyer, MD

How to diagnose nonpigmented skin tumors: A review of vascular structures seen with dermoscopy

Part I. Melanocytic skin tumors

Iris Zalaudek, MD,[a] Jürgen Kreusch, MD, PhD,[b] Jason Giacomel, MBBS,[c] Gerardo Ferrara, MD,[d]
Caterina Catricalà, MD,[e] and Giuseppe Argenziano, MD, PhD[f]

(J Am Acad Dermatol 2010;63:361-74.)

How to diagnose nonpigmented skin tumors: A review of vascular structures seen with dermoscopy

Part II. Nonmelanocytic skin tumors

Iris Zalaudek, MD,[a] Jürgen Kreusch, MD, PhD,[b] Jason Giacomel, MBBS,[c] Gerardo Ferrara, MD,[d]
Caterina Catricalà, MD,[e] and Giuseppe Argenziano, MD, PhD[f]

(J Am Acad Dermatol 2010;63:377-86.)

Pattern Vascolare della cute normale

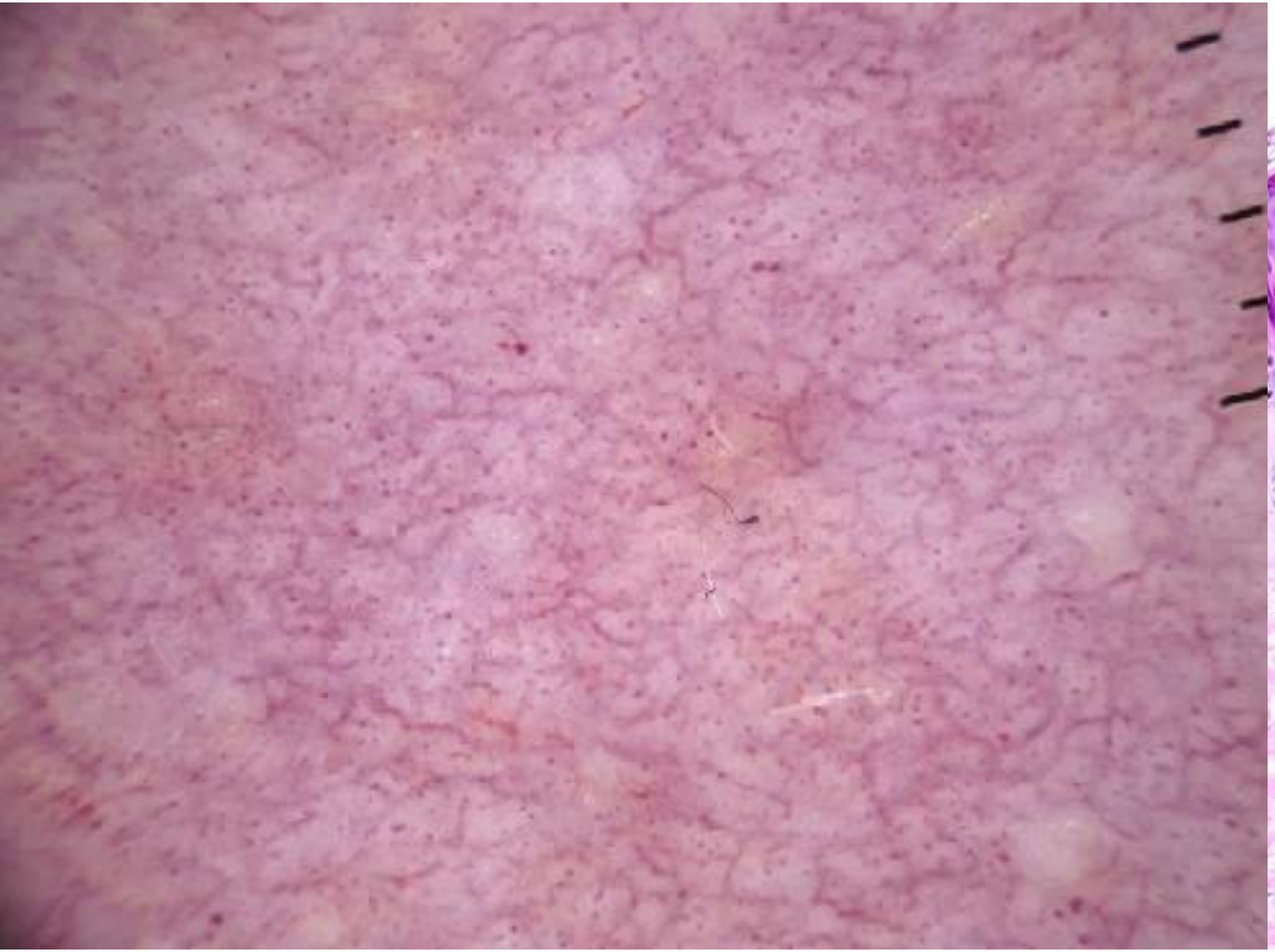

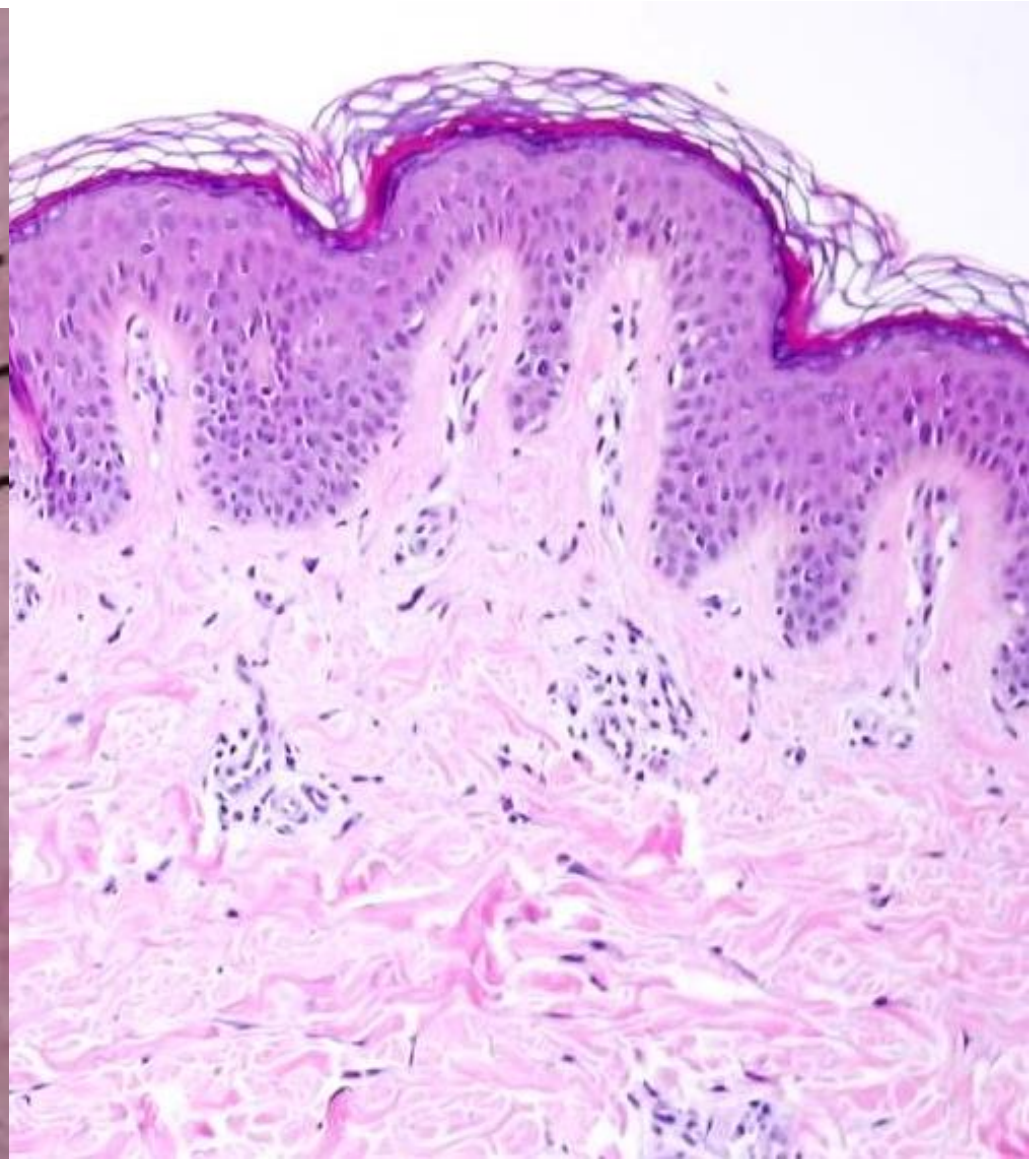

Correlazioni dermoscopico-patologiche
Pattern vascolare

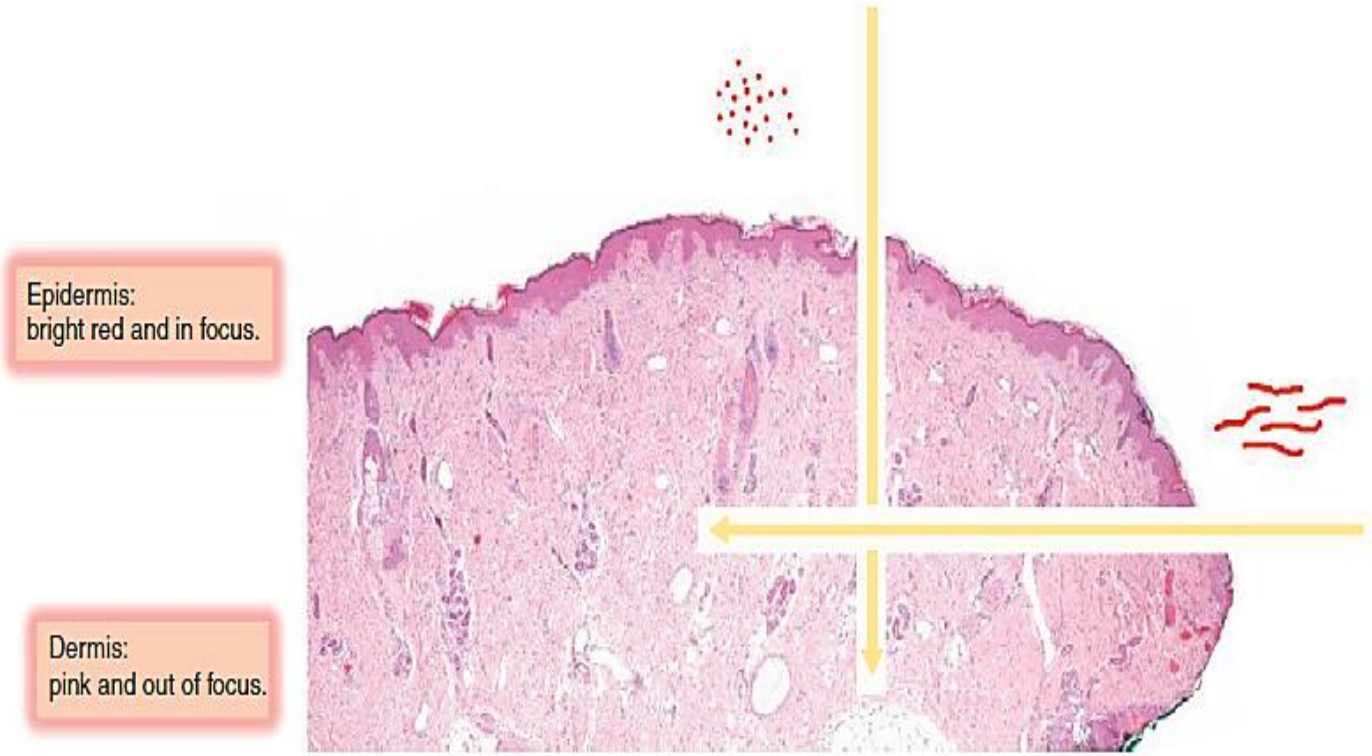

Figure 1 Dermoscopic morphologic features of vessels according to their location in the skin.

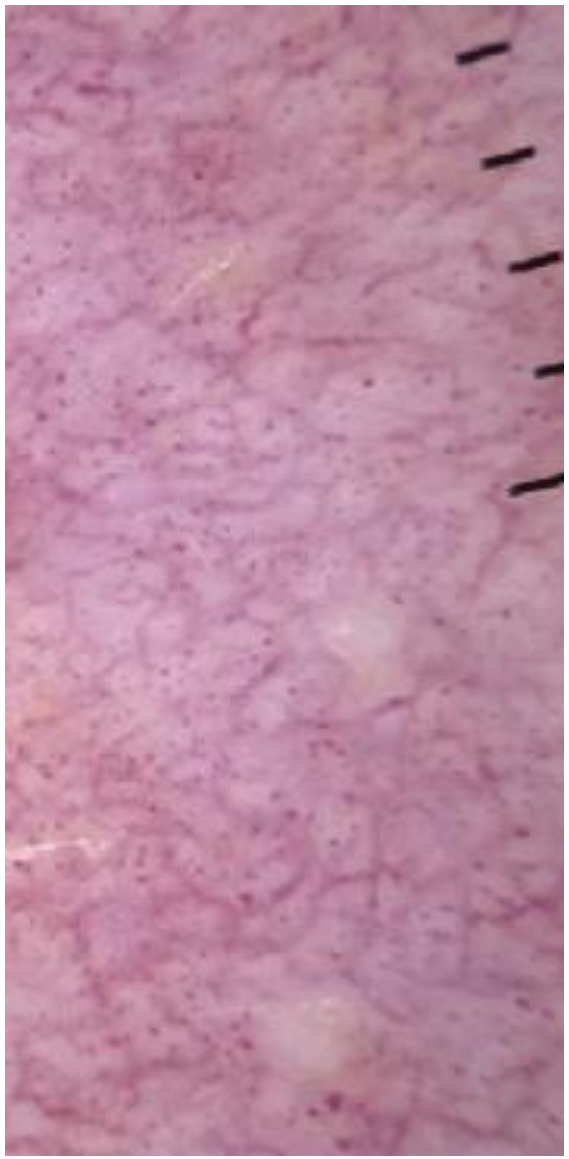

Morfologia delle strutture vascolari

Vascular Pattern	Description	Interpretation	Diagram
Arborizing vessels or telangiectasias	In-focus large -caliber vessels that branch into finer secondary vessels	- Basal cell carcinoma - Adnexal tumors	
Hairpin vessels	Vessels that double back on themselves and are seen as loops when they are oblique to the surface of the lesion; in keratinizing tumors, they are surrounded by a hypopigmented halo	- Regular: seborrheic keratosis - Irregular: melanoma, Spitz nevus, and keratoacanthoma	
Crown vessels	Barely branching peripheral vessels that do not cross the center of the lesion	-Sebaceous hyperplasia - Molluscum contagiosum	
Comma vessels	Thick, linear curved lines with little branching and occasionally one end that is thicker than the other	- Compound or dermal nevus	
Dotted vessels	Small-caliber reddish vessels that resemble a pinhead	- Spitz nevus - Melanoma - Inflammatory lesions	
Glomerular vessels	Larger-caliber reddish dots formed by tortuous capillaries curled up into a ball or resembling the glomerular apparatus of the kidneys	- Bowen disease - Stasis dermatitis	
Corkscrew vessels	Linear irregular spiral vessels areas containing atypical linear vessels	- Melanoma - Melanoma metastasis	
Milky-red areas/globules	Out-of-focus pink-reddish oval or polygonal areas containing atypical linear vessels	- Melanoma	
Strawberry pattern	Structureless erythematous areas with heterogeneous whitish areas forming a type of pseudonetwork	- Melanoma - Superficial basal cell carcinoma	
Linear irregular vessels	Straight vessels varying in shape and size	- Melanoma	
Polymorphous vessels	Different vascular morphologies in the same lesion	- Melanoma - Carcinomas	

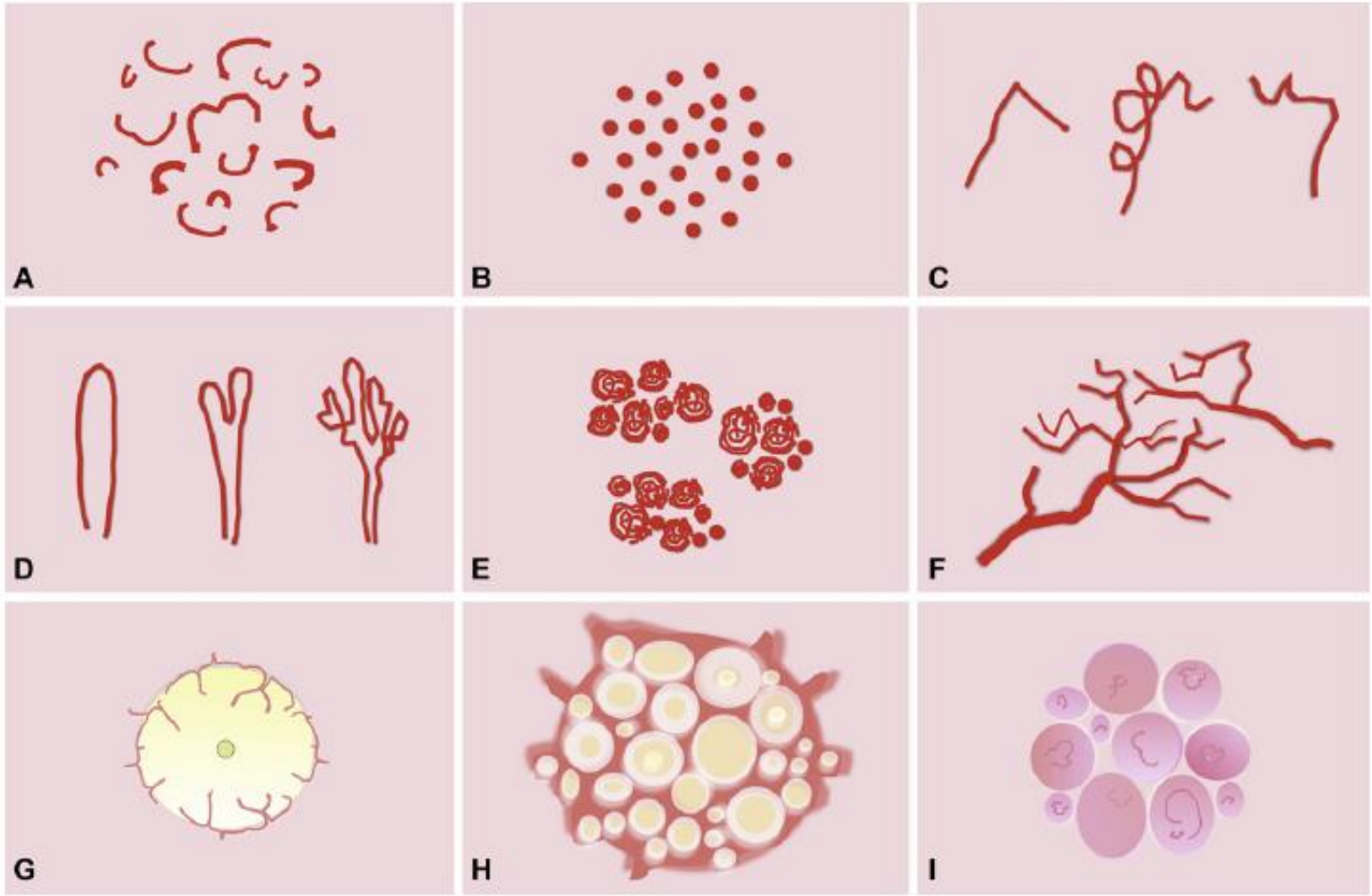

J Am Acad Dermatol 2010;63:361-74

Disposizione delle strutture vascolari

Vascular Pattern	Description	Example	Diagram
Regular	Vessels distributed evenly through the lesion	- Spitz nevus	
String of pearls	Dotted vessels arranged linearly in a pattern that resembles a string of pearls	- Clear-cell acanthoma	
Clustered	With a tendency to group together in a lesional area	- Bowen disease	
Radial	Presence of vessels only at the periphery of the lesion; they do not occupy or cross the center	- Sebaceous hyperplasia	
Branching	Large vessels that branch into smaller vessels	- Basal cell carcinoma	
Irregular	Vascular polymorphism without a specific pattern	- Melanoma	
Rope-ladder pattern	Short, slightly dilated loops that emerge from the edges of the scar and cross it completely	- Scar	

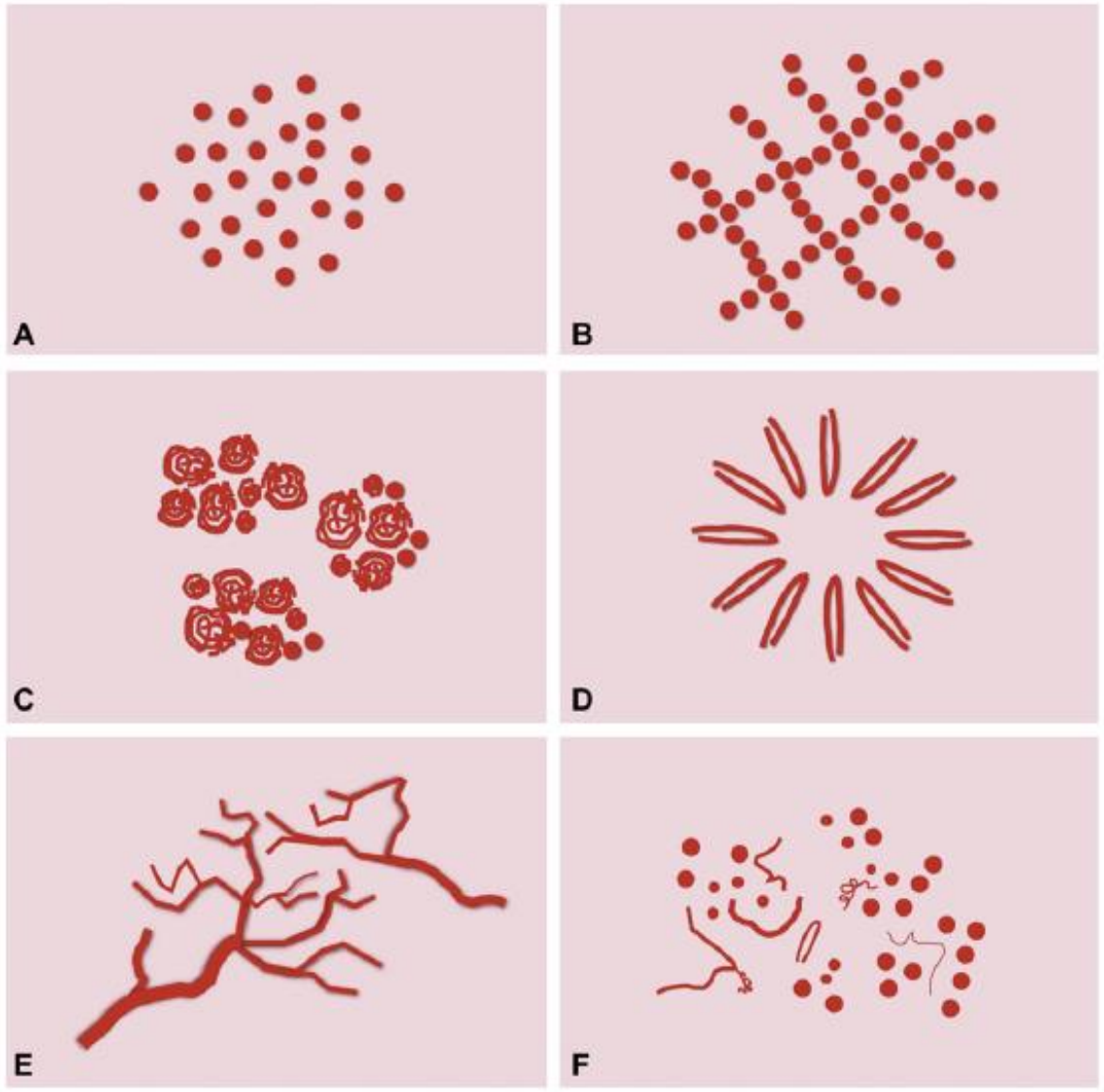

J Am Acad Dermatol 2010;63:361-74

Vascular Morphology
Dotted
Comma
Glomerular
Crown
Hairpin
Linear irregular
Milky-red globules

Vascular Morphology
Arborizing
Short fine arborizing
Lacunes
Reddish pseudonetwork
Red homogeneous color
Corkscrew 
Polymorphous (atypical) vascular pattern

Vascular Pattern	Definition
Regular	Vessels that are arranged fairly regularly throughout lesion (eg, the arrangement of hairpin vessels in SK, comma vessels in dermal nevi, and dot vessels in Spitz nevus or thin AHM)
Irregular	Vessels distributed irregularly throughout tumor; for example, polymorphous vessels in invasive SCC or melanoma (pictured) or the irregular distribution of arborizing telangiectasias in BCC
Clustered	Pattern wherein vessels are arranged in clustered groups, classically referring to glomerular vessels in Bowen disease
Stringlike (or reticular)	Vessels arranged in lines, which may crisscross to form a peculiar reticular pattern; usually refers to the distribution of dotted and/or tortuous (ie, coiled or glomerular) vessels in CCA, but this pattern may also be seen in LCA
Radial	Vessels are distributed around the periphery of the tumor; stereotypical example, radial arrangement of hairpin vessels in KA (surrounding a central keratin mass)
Strawberry 	A pattern seen in facial AK, comprising a reddish pseudonetwork around hair follicles; fine, linear-wavy vessels may also surround the follicles; hair follicle openings often filled with yellowish keratotic plugs and surrounded by a white halo

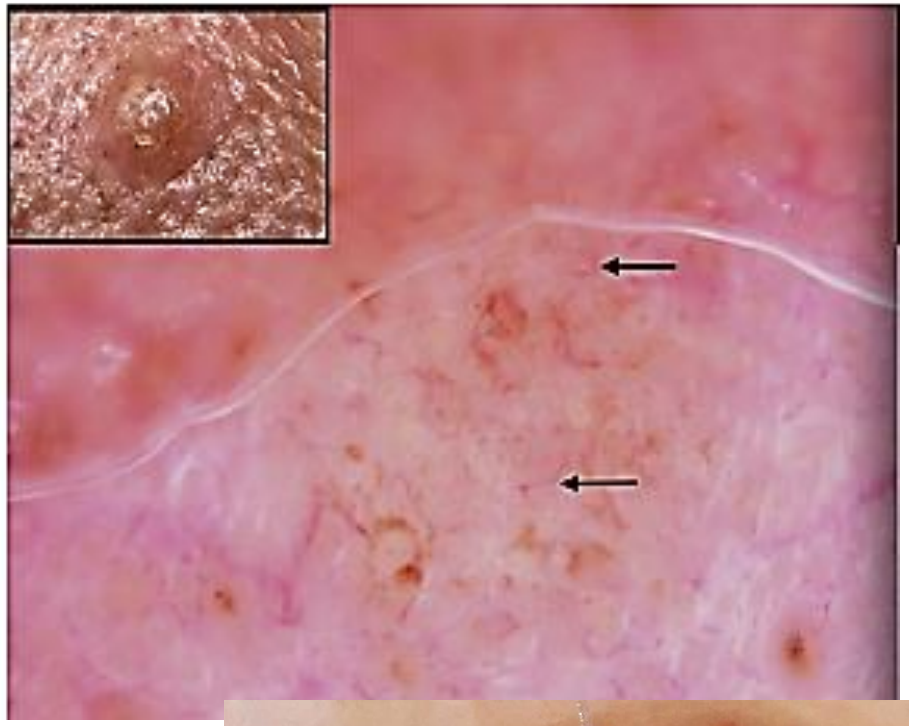

Comma

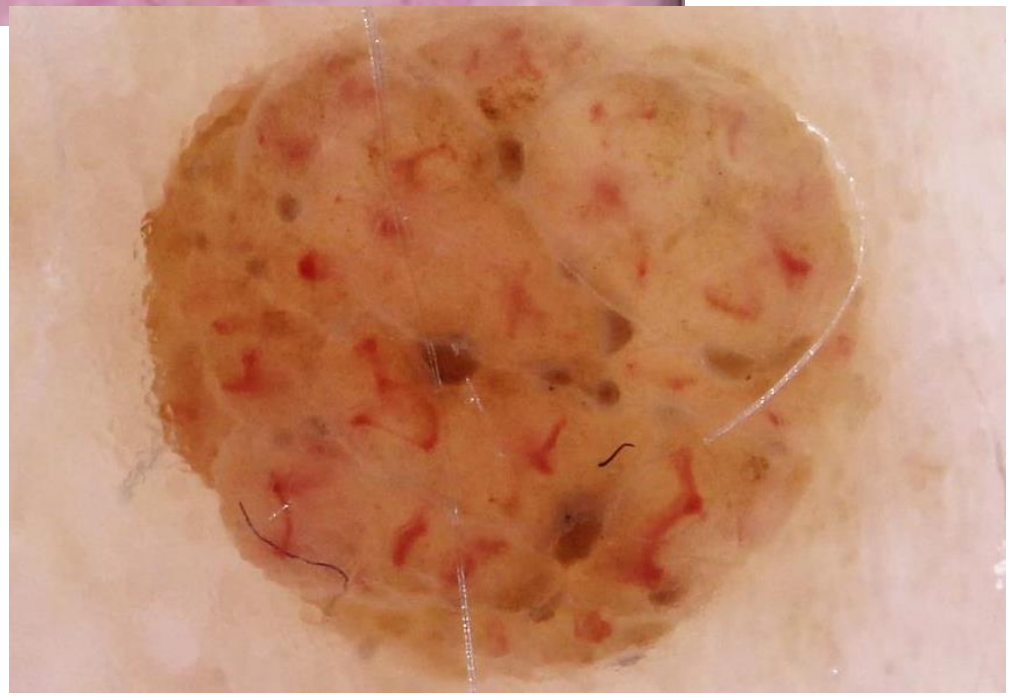

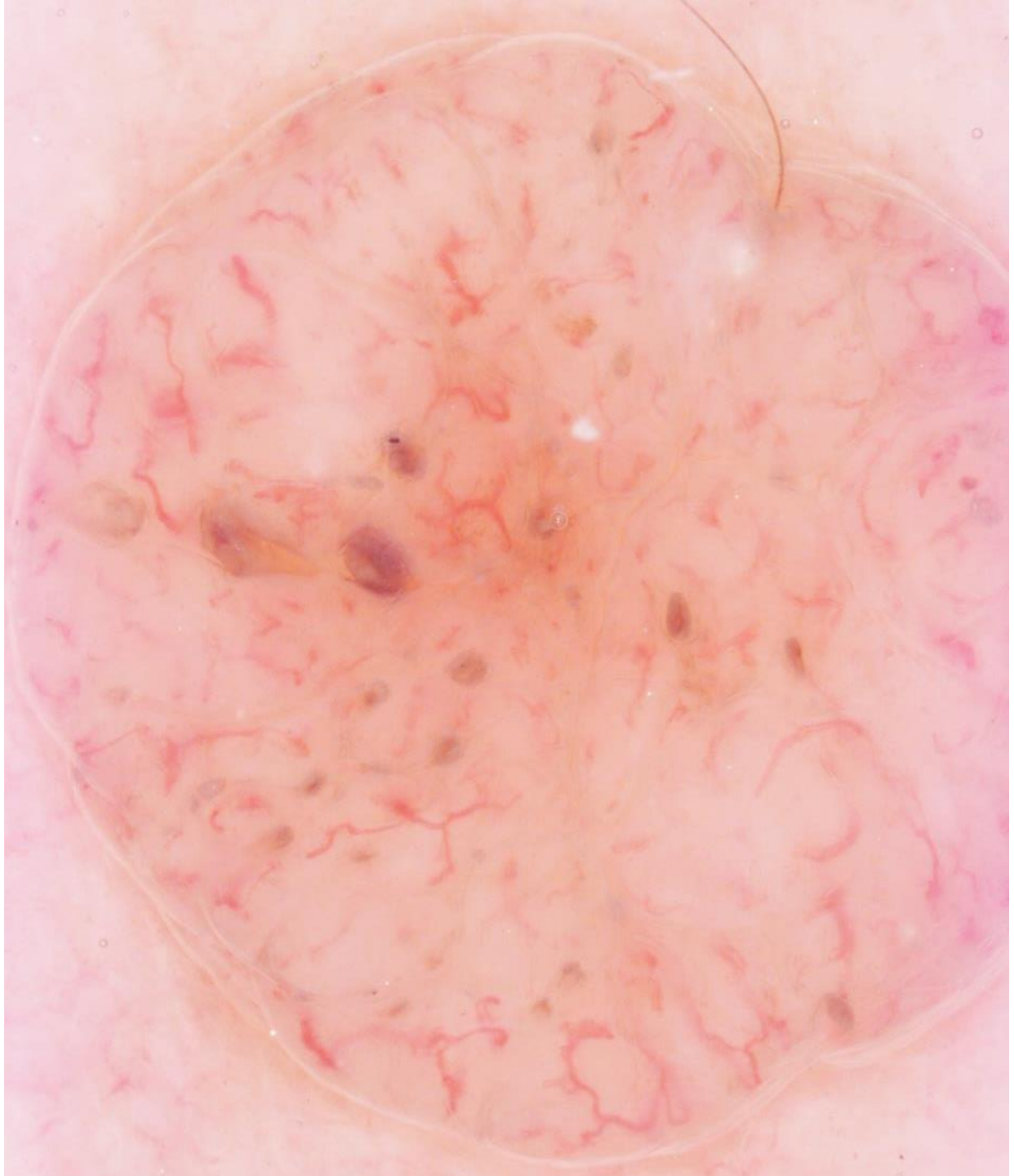

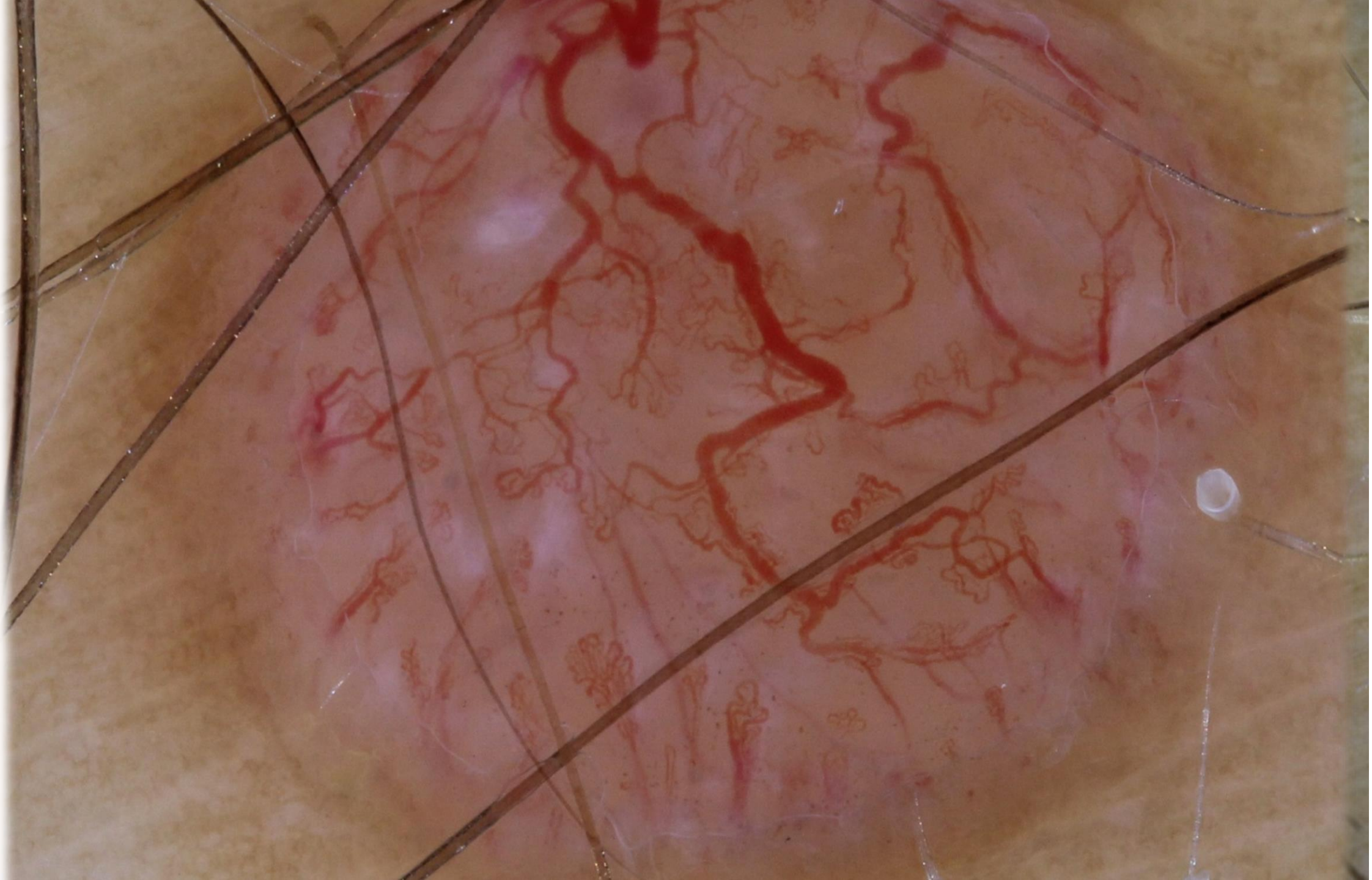

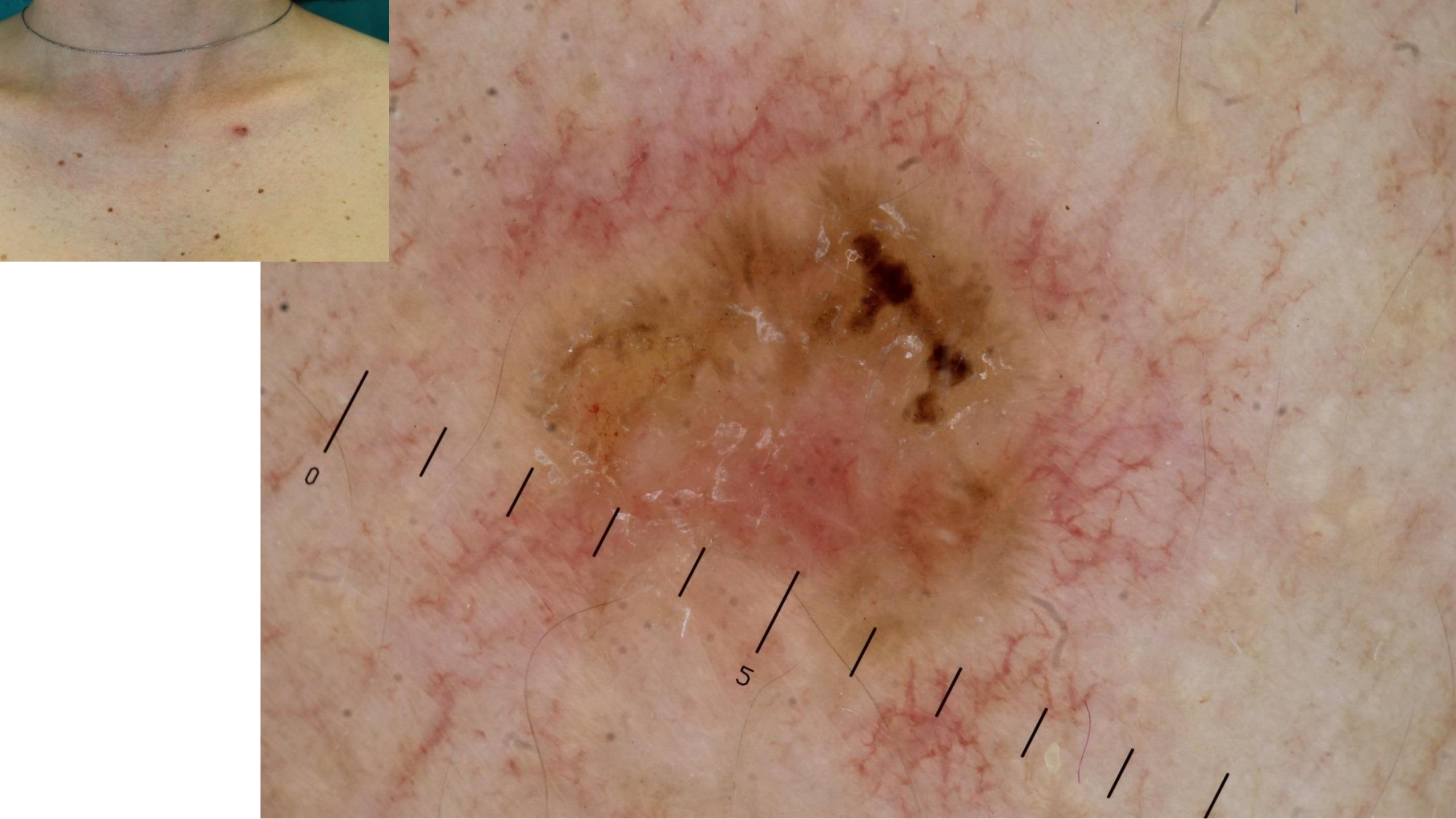
0
5

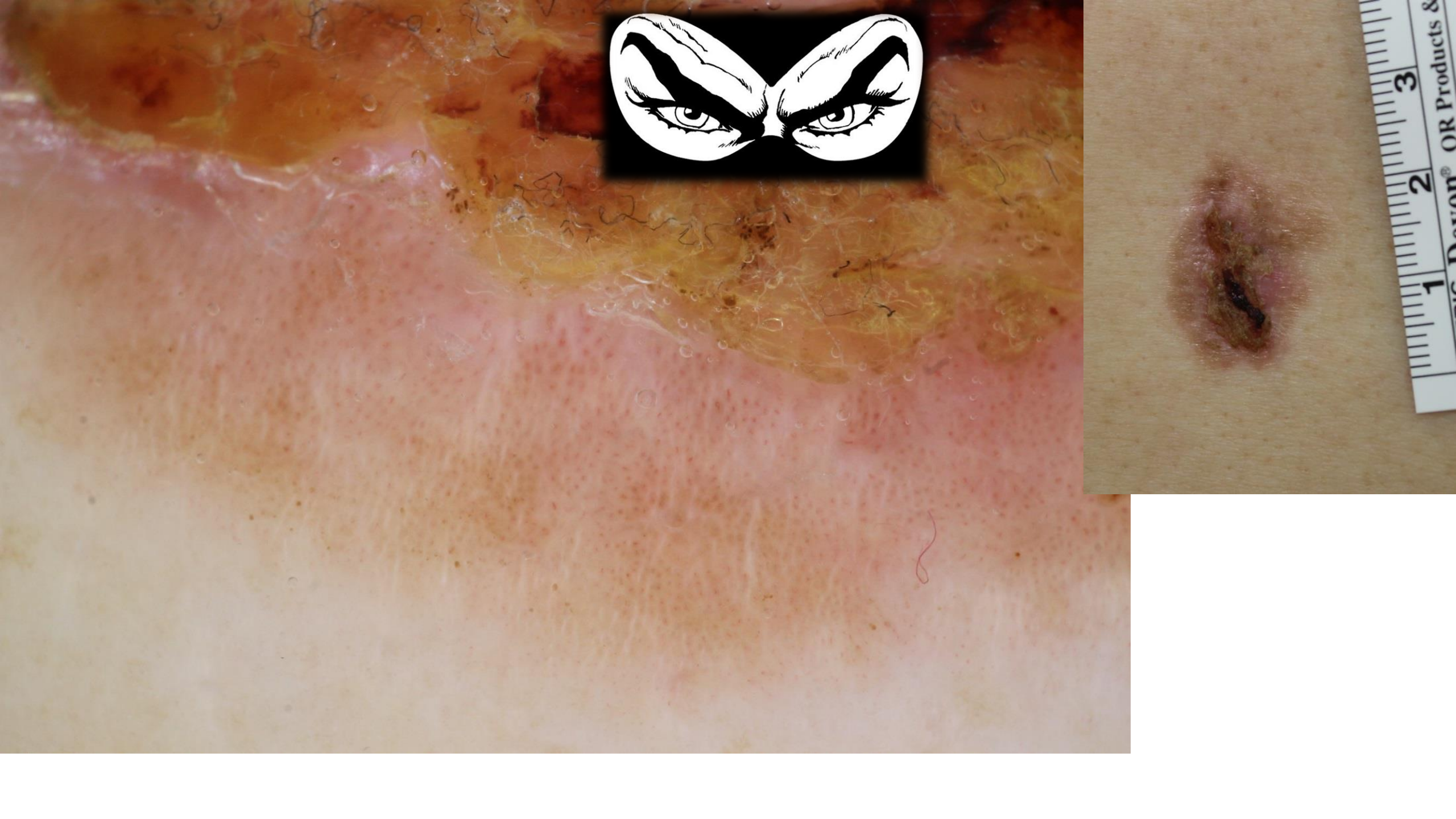

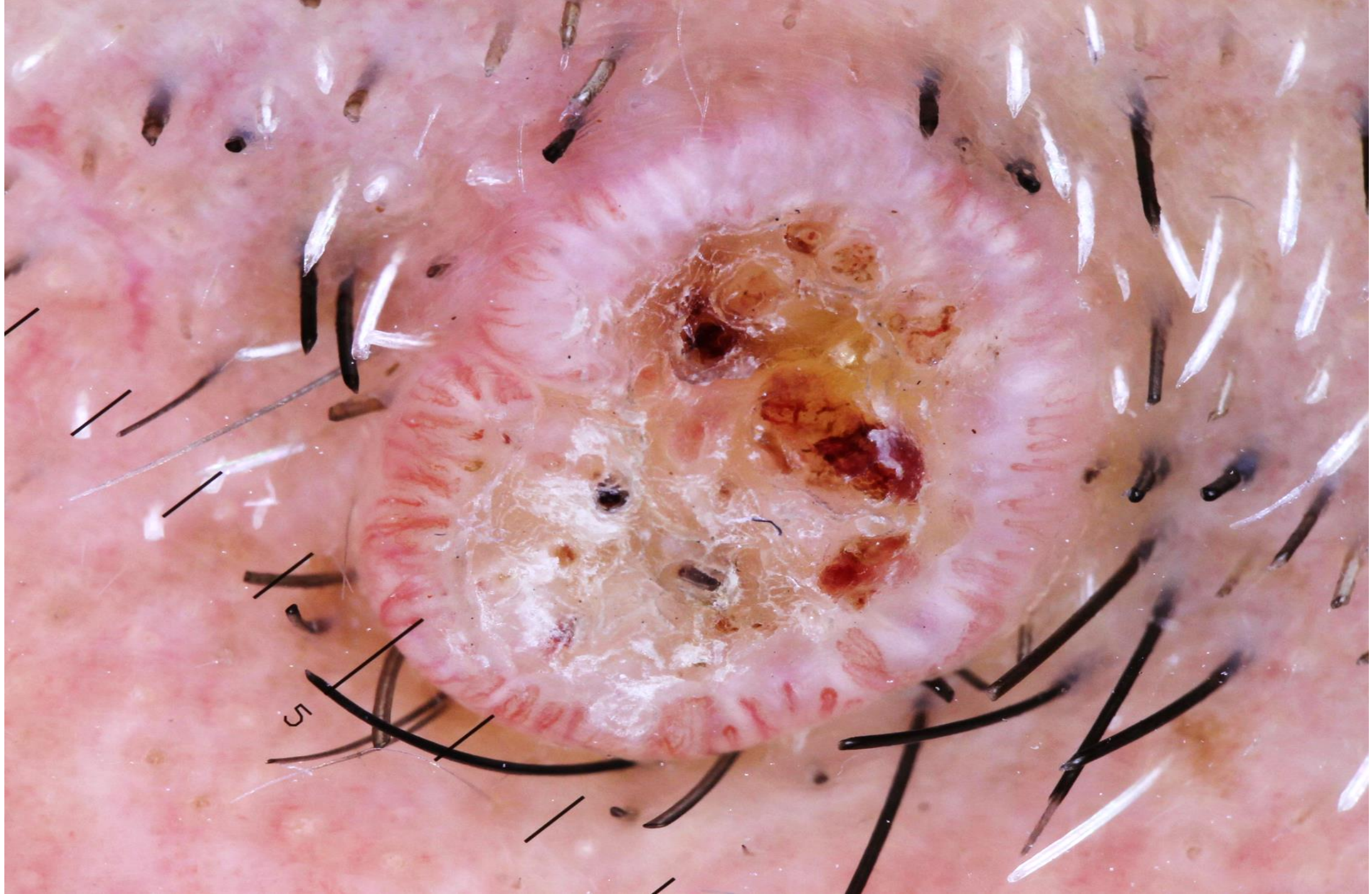
5

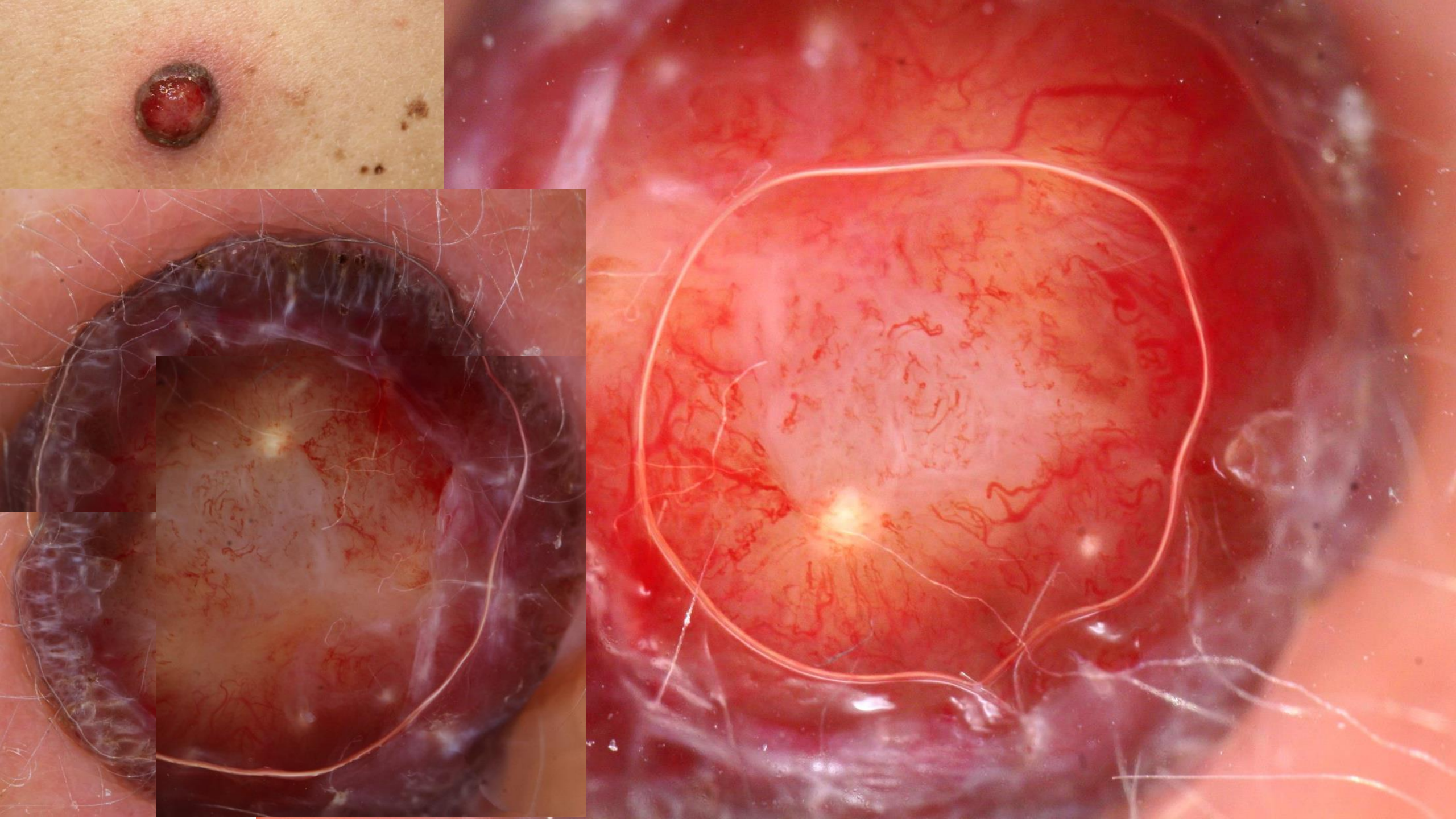

Pattern vascolare nel melanoma

Il polimorfismo vascolare è direttamente proporzionale allo spessore del melanoma

- Breslow < 1mm → vasi puntiformi
- Breslow 1-2 mm → vasi puntiformi e vasi lineari-irregolari
- Breslow >2 mm → pattern vascolare polimorfo con aree rosso-lattescenti di fondo

Zalaudek JAAD 2010

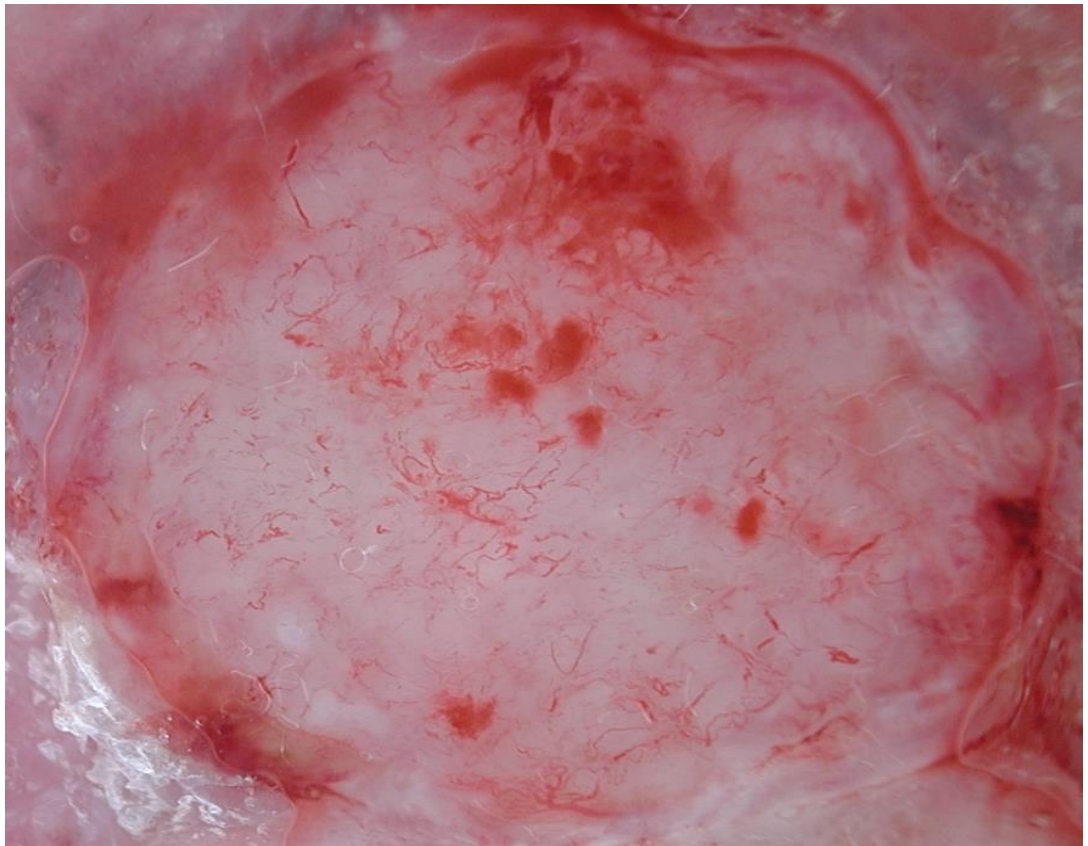

F 65 – braccio

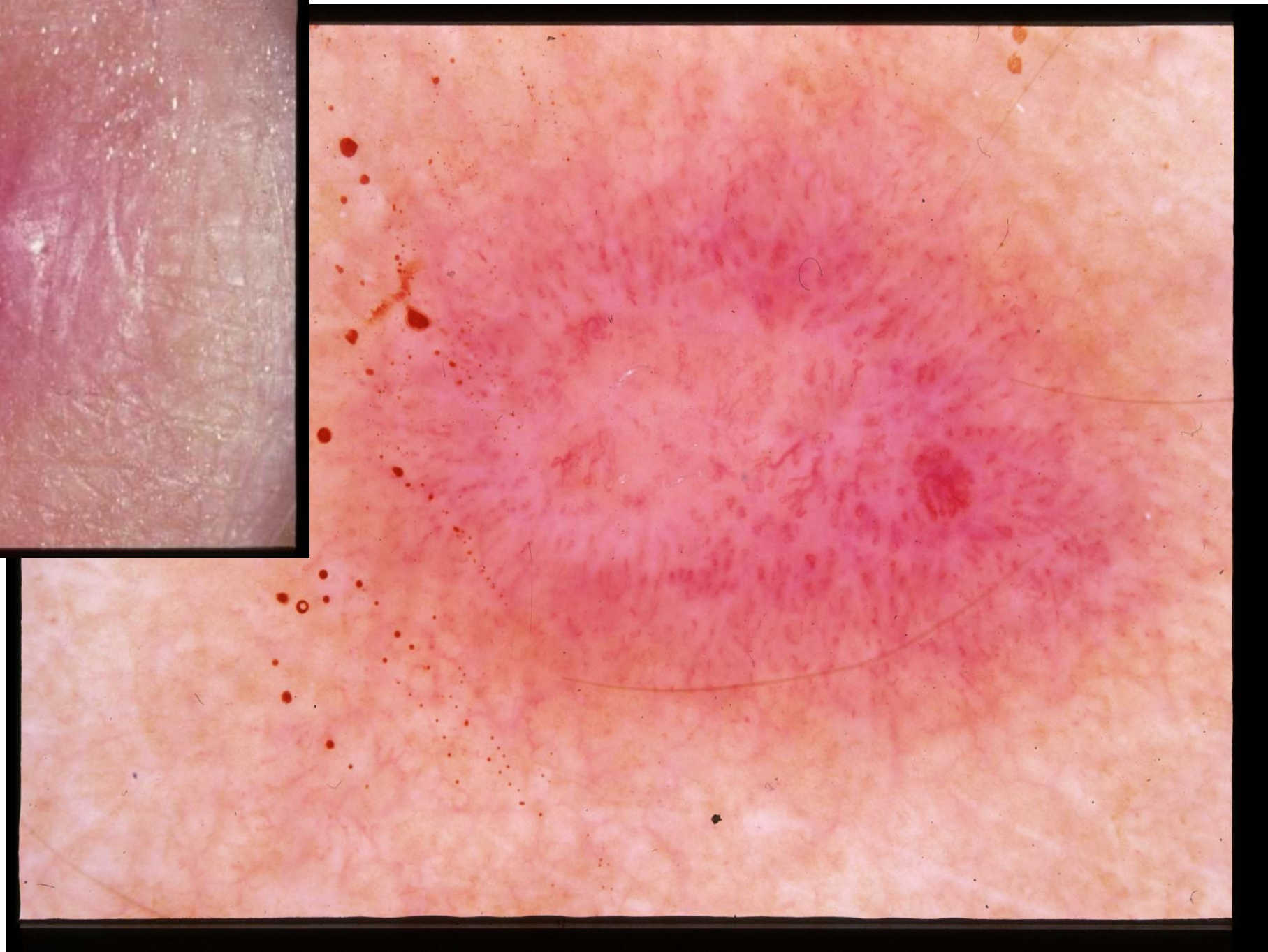

Courtesy of Peter Soyer

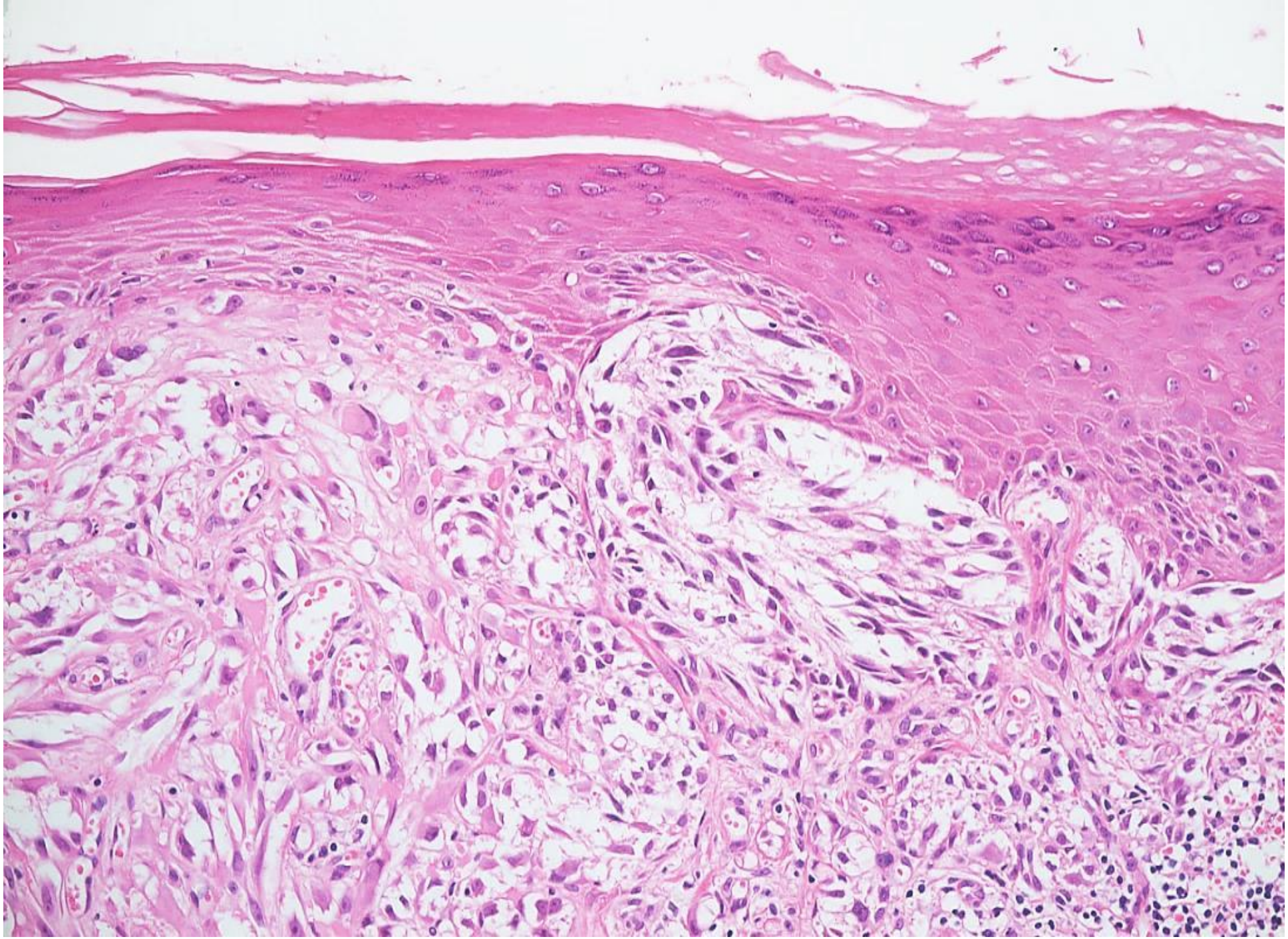

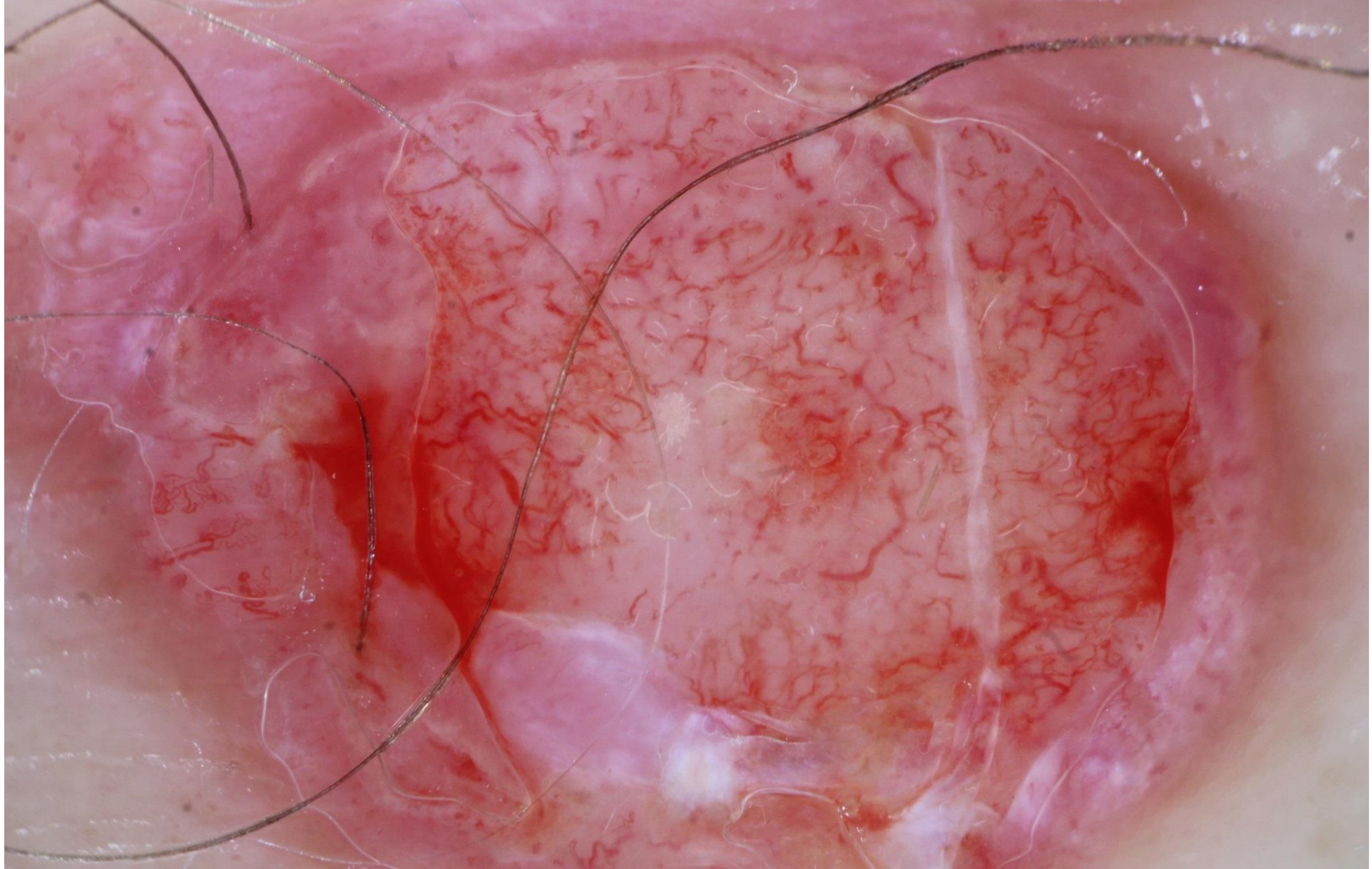

BCC

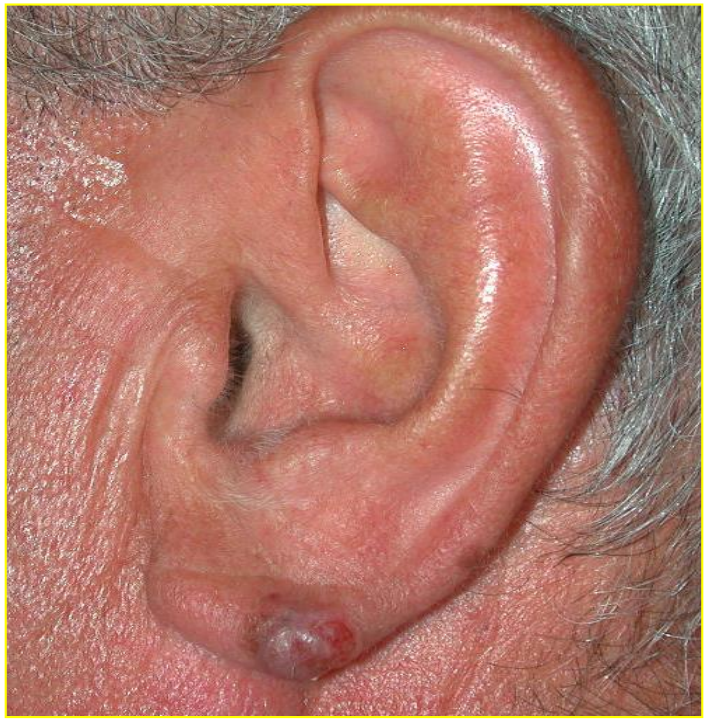

MM amelanotico

SCC

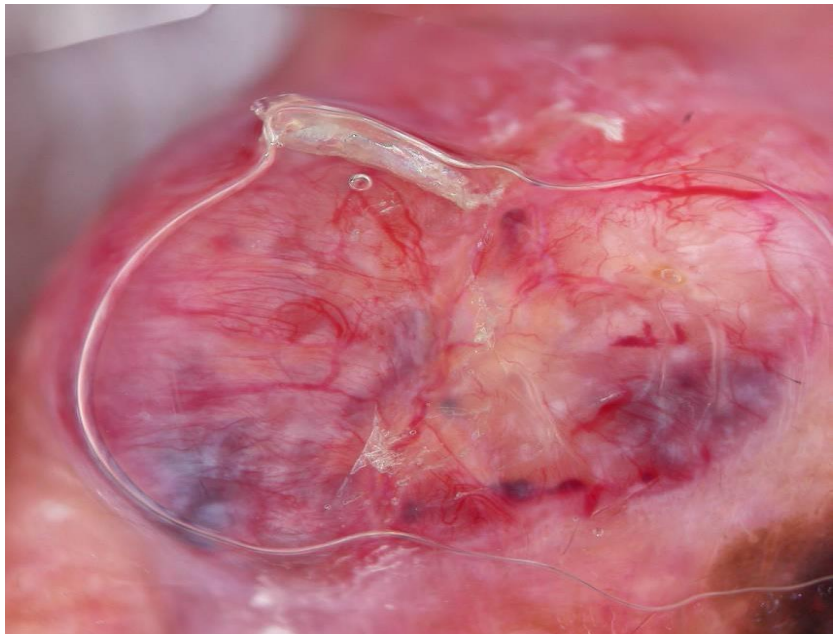

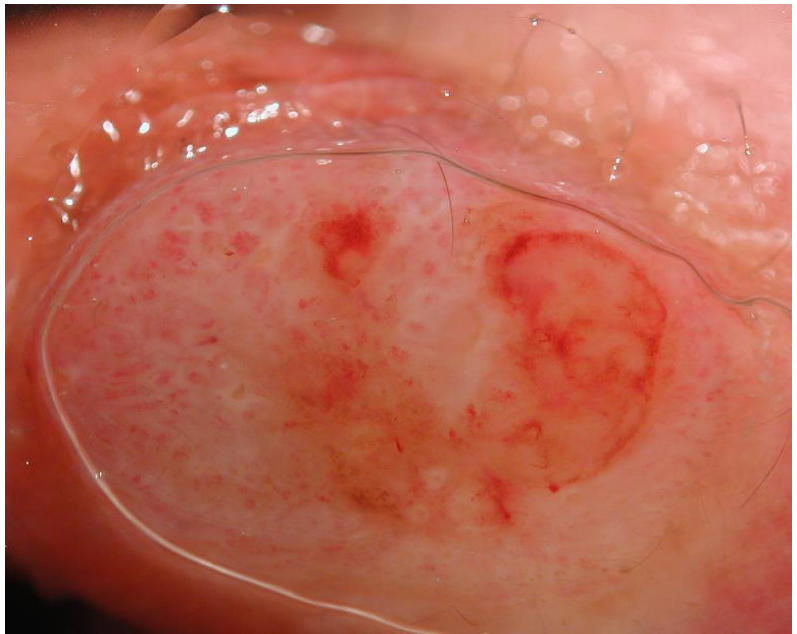

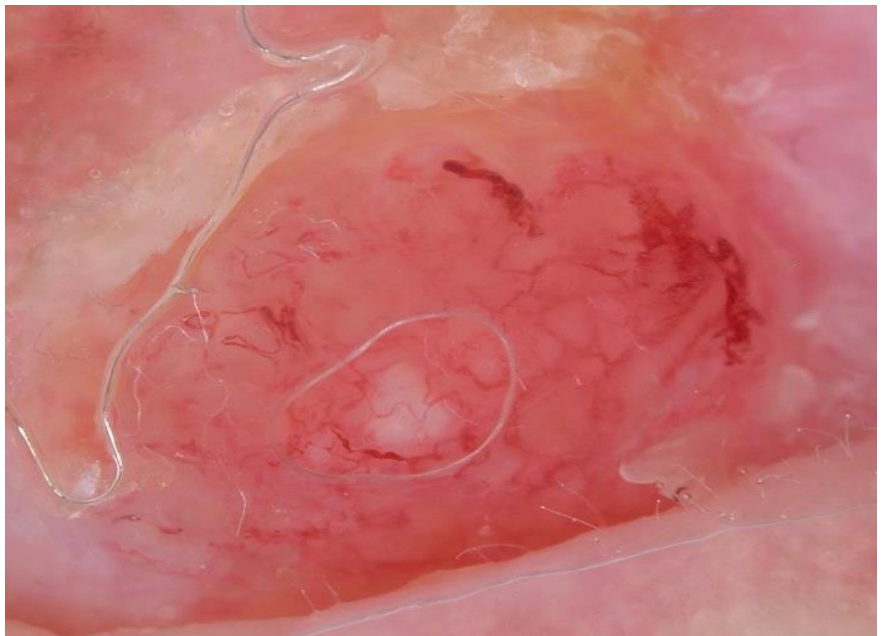

Nodules With a Prominent Vascular Component

ARCH DERMATOL/VOL 144 (NO. 5), MAY 2008 WWW.ARCHDERMATOL.COM

Anna Sgambato, MD; Iris Zalaudek, MD; Gerardo Ferrara, MD; Caterina M. Giorgio, MD; Elvira Moscarella, MD; Rachele Nicolino, MD; Giuseppe Argenziano, MD; Department of Dermatology, Second University of Naples, Naples, Italy

- Skin tumors with a prominent vascular component should be considered for biopsy
- especially when elevated, firm, and growing

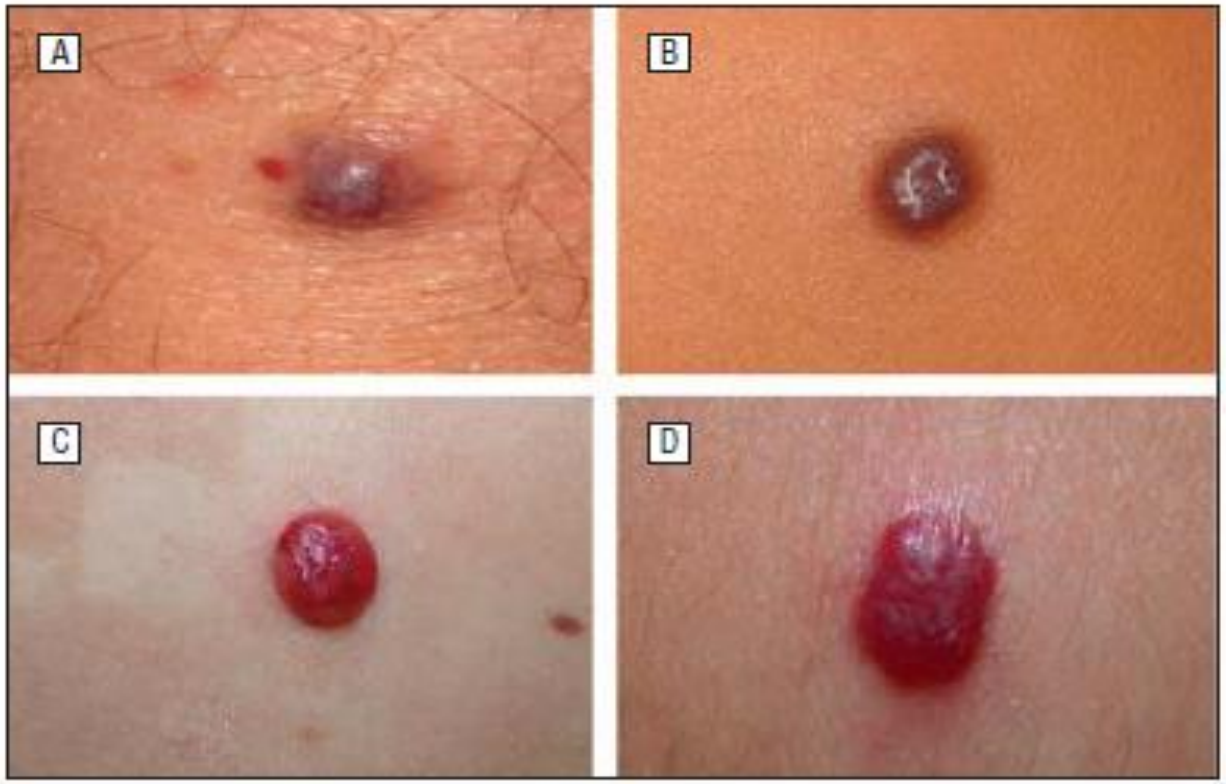

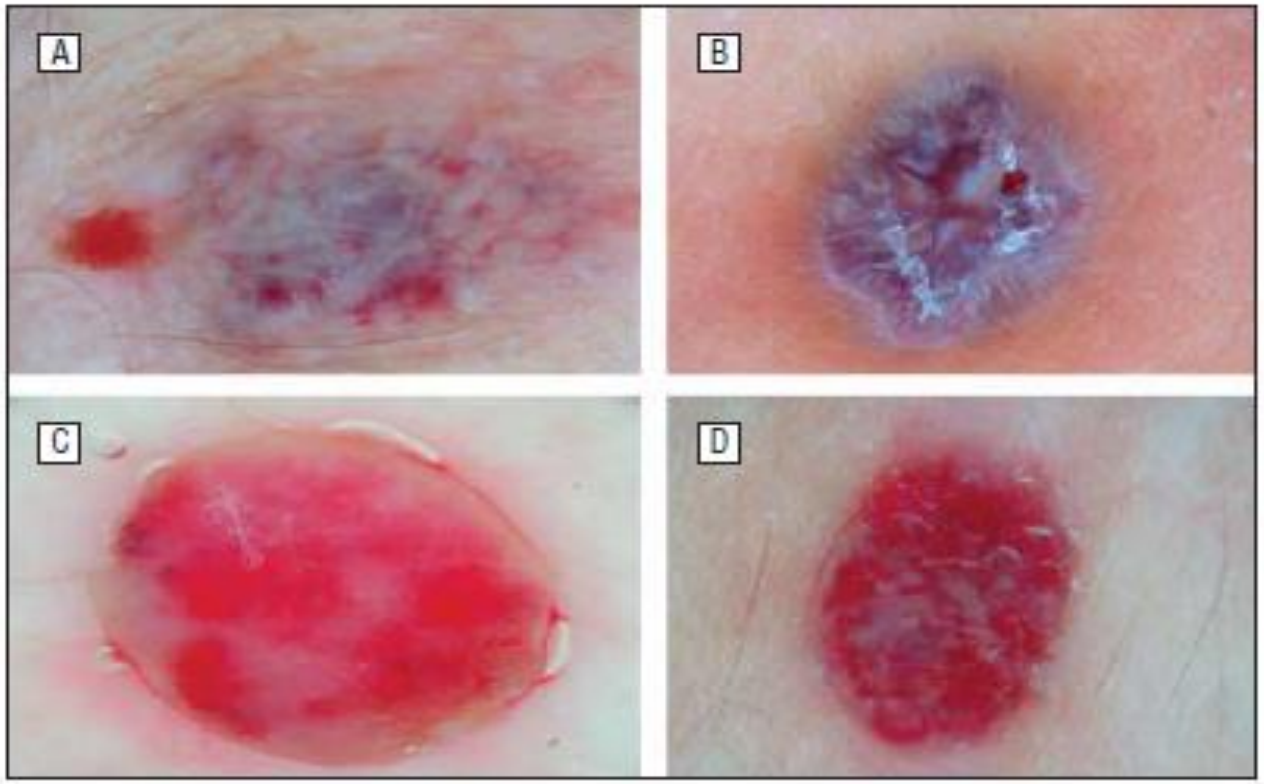

Pink / featureless lesions

1. *Pattern Vascolari*
2. *Criteri per diagnosi specifiche*

Criteri dermoscopici aggiuntivi

Lesion	**Mature Melanocytic Nevus**	**Spitz Nevus**	**Dysplastic Nevus**	**Melanoma**	**Clear-Cell Acanthoma**	**Basal Cell Carcinoma**
Type of vessels	Comma	Dotted	Dotted and comma	Thin tumors (< 1 mm): dotted vessels Intermediate tumors (1-2 mm): dotted and linear irregular vessels Thick tumors: polymorphous vessels	Dotted	Telangiectasias
Distribution	Regular	Regular	Regular/irregular	Irregular	String of pearls	Branching
Additional criteria	- Comedo-like openings/milia-like cysts - Terminal hair - Residual brown pigmentation	- Pink background - Melanocytic criteria: -Inverted network - Chrysalis structures	-Melanocytic criteria	- Atypical melanocytic criteria: - Chrysalis structures	-Erythematous background	- Blue-gray nests and ovoid globules - Maple leaf-like areas - Wheel spoke areas - Ulceration
Diagram		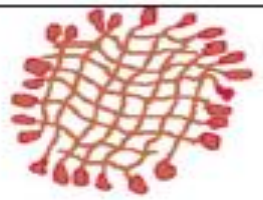		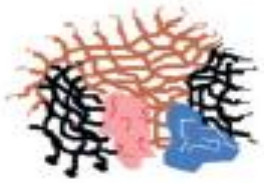		

Actas Dermosifiliogr. 2012;103(5):357–375

Courtesy of Geppi Argenziano

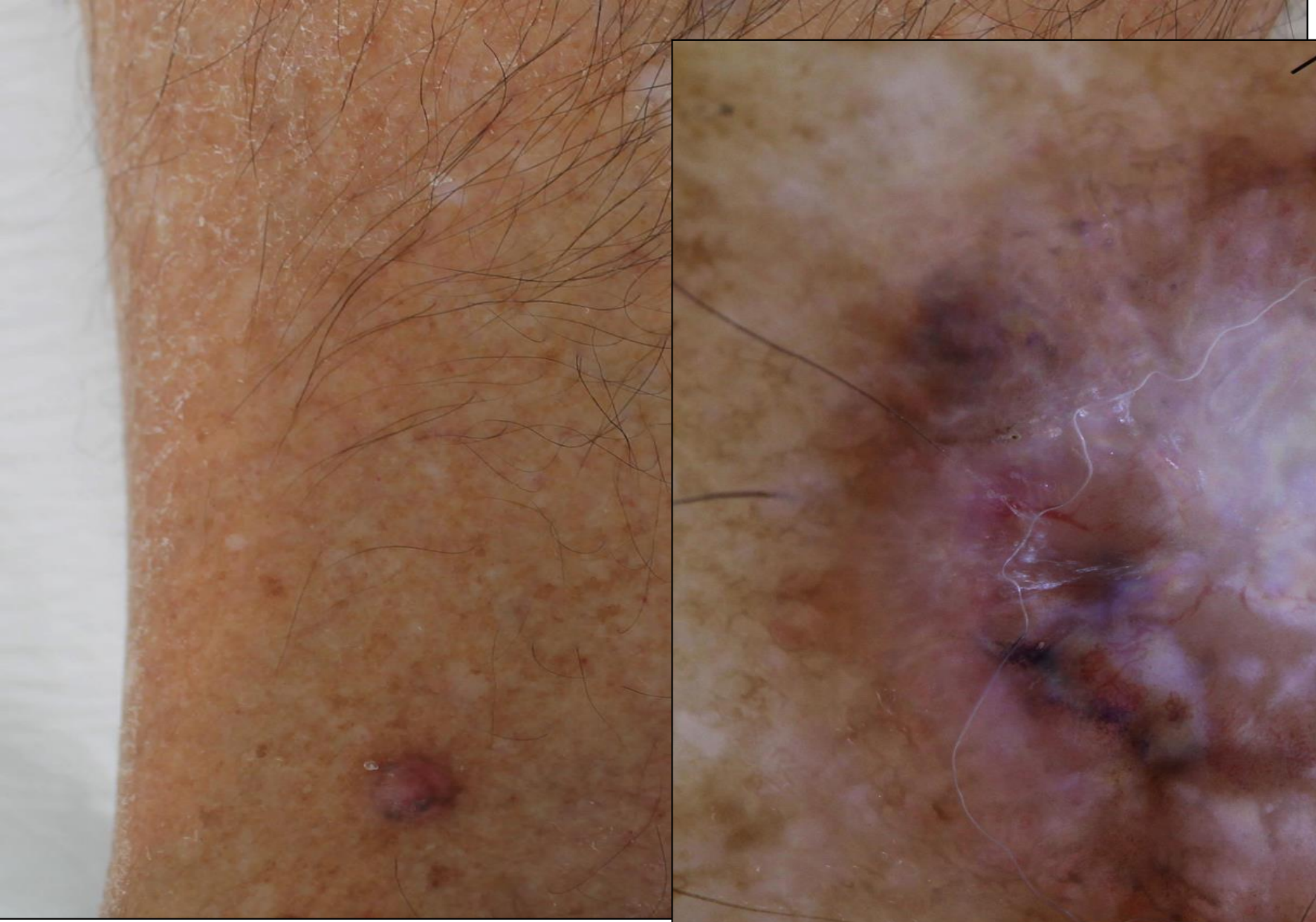

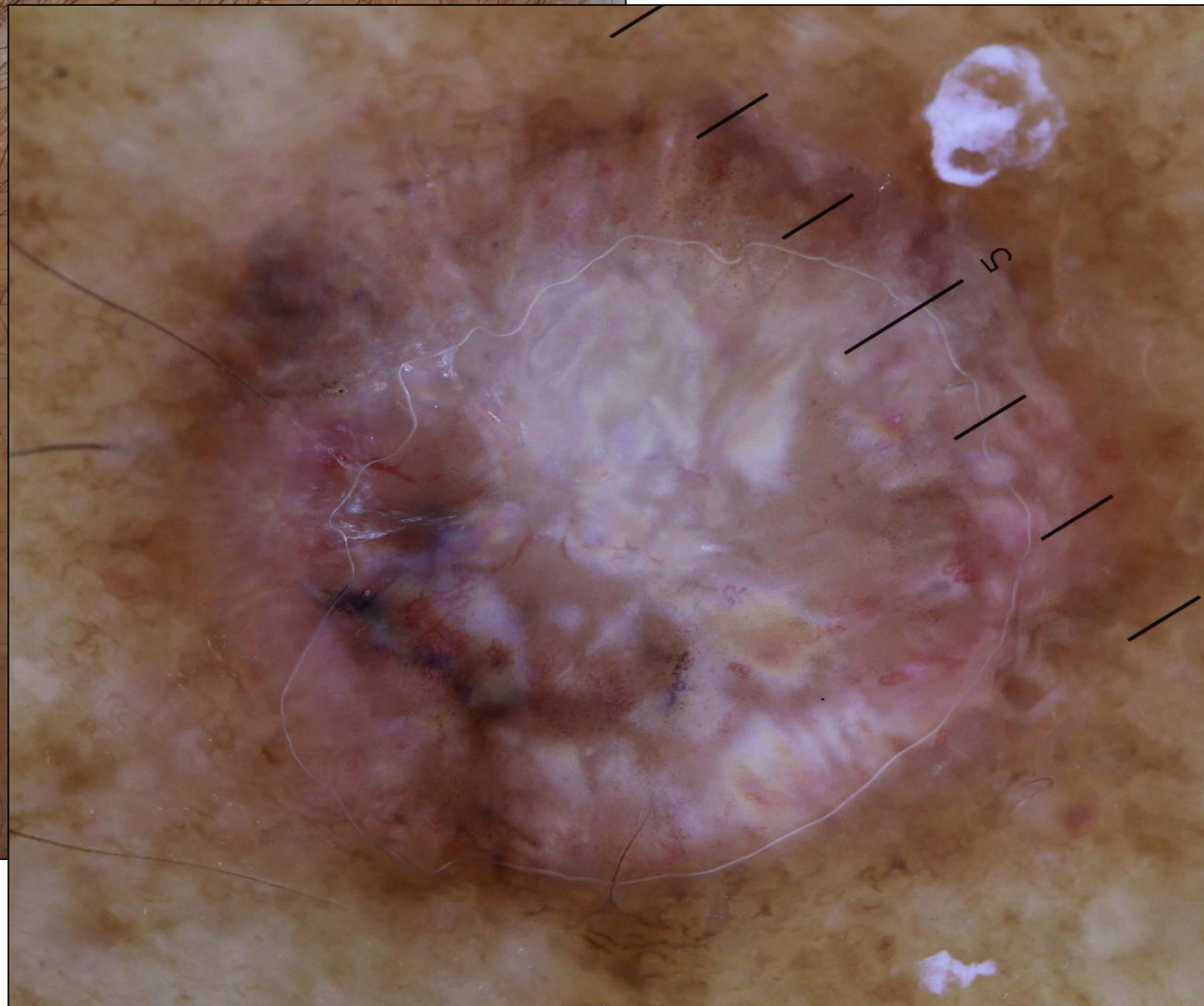

M, 74 anni,

Criteri dermoscopici aggiuntivi

Lesion	Seborrheic Keratosis	Hypopigmented actinic keratosis	Bowen Disease	Squamous Cell Carcinoma	Sebaceous Hyperplasia/Molluscum contagiosum	Dermatofibroma
Type o vessels	Hairpin with peripheral whitish halo	Dotted	Glomerular	Hairpin	Crown	Dotted (30%)
Distribution	Regular	Regular	Clustered	Radial	Radial	Not defined
Additional criteria	- Milia-like cysts - Comedo-like openings - Fissures and crests - Fingerprint structures - Sharp demarcation	- Raspberry pattern - Rosette sign	- Superficial scaling - Erythematous background	- Whitish peripheral halo - Kyperkeratosis	- Whitish peripheral halo - Hyperkeratosis	- Pigmented peripheral network - Central white patch
Diagram		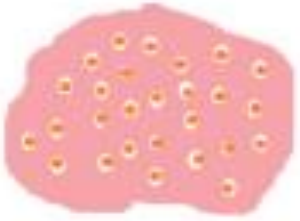				

Actas Dermosifiliogr. 2012;103(5):357–375

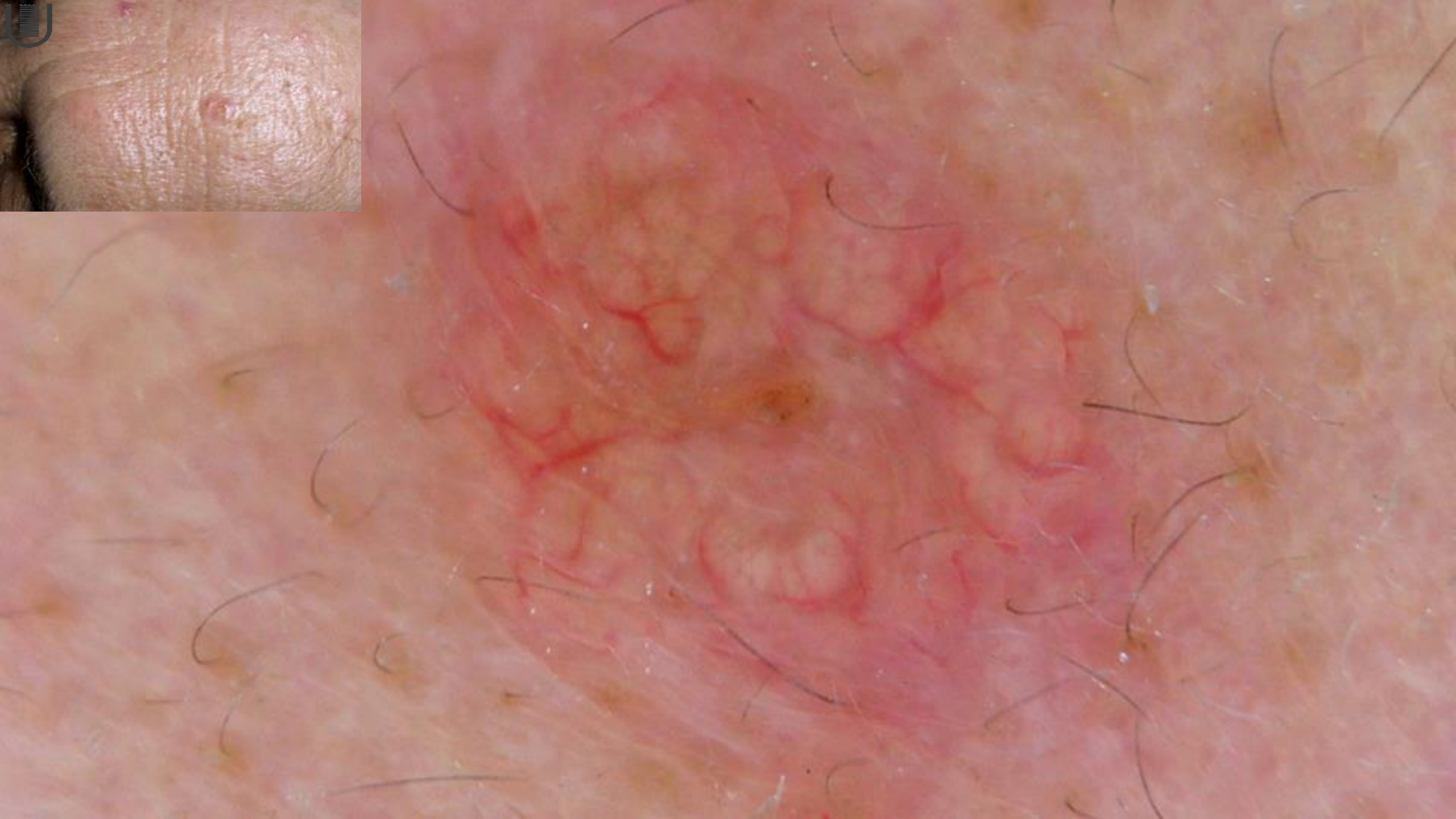

Courtesy of Andrea Gulia

Dermatoscopy of facial actinic keratosis, intraepidermal carcinoma, and invasive squamous cell carcinoma: A progression model

Iris Zalaudek, MD,[a] Jason Giacomel, MBBS,[b] Karin Schmid, DSc,[c] Silvia Bondino, MD,[d] Cliff Rosendahl, MBBS,[e] Stefano Cavicchini, MD,[f] Athanasia Tourlaki, MD,[f] Saturnino Gasparini, MD,[g] Peter Bourne, MBBS,[h] Jeff Keir, MBBS,[i] Harald Kittler, MD,[j] Laura Eibenschutz, MD,[k] Caterina Catricalà, MD,[k] and Giuseppe Argenziano, MD[l]

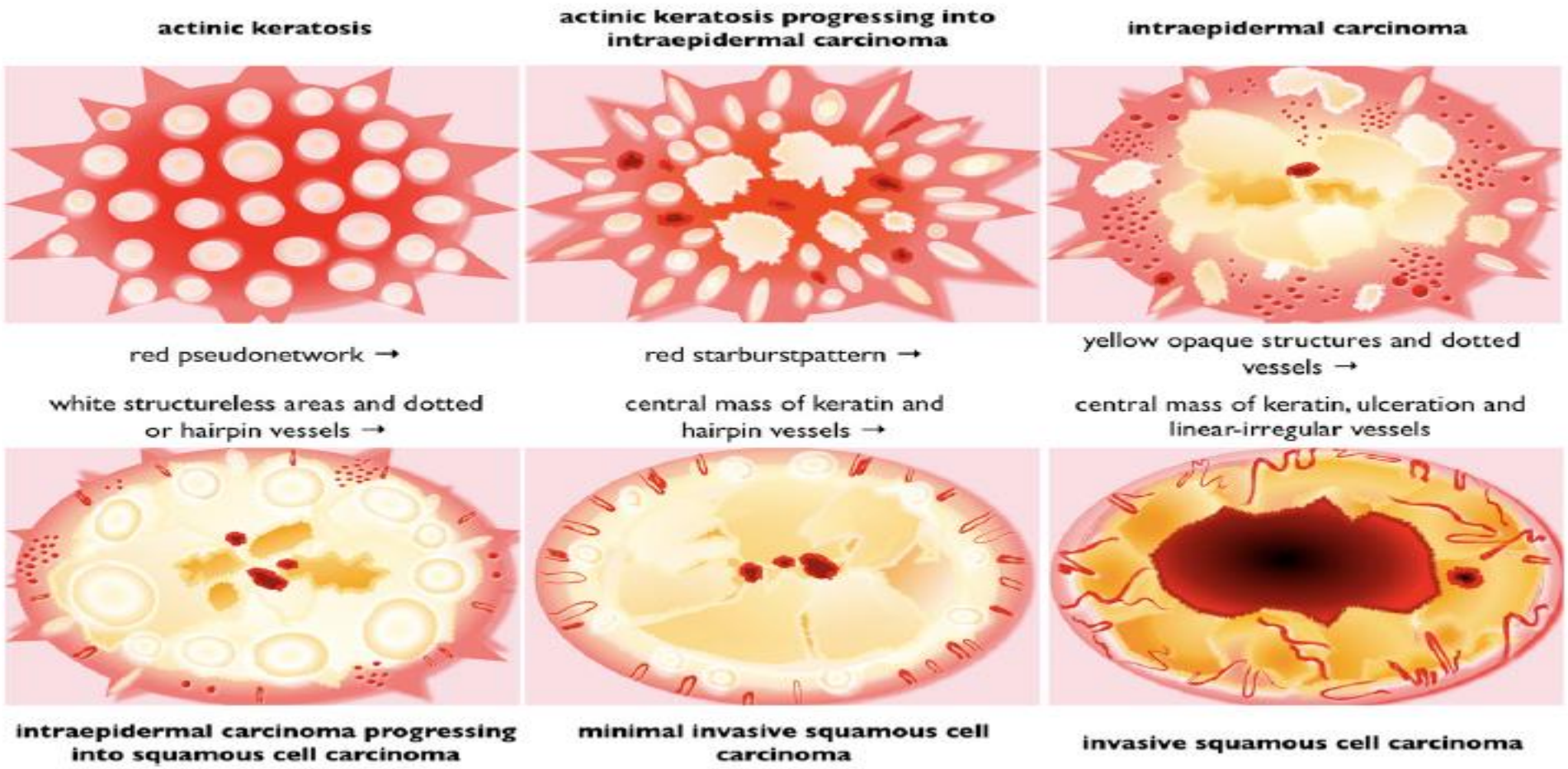

J Am Acad Dermatol 2012;66:589-97

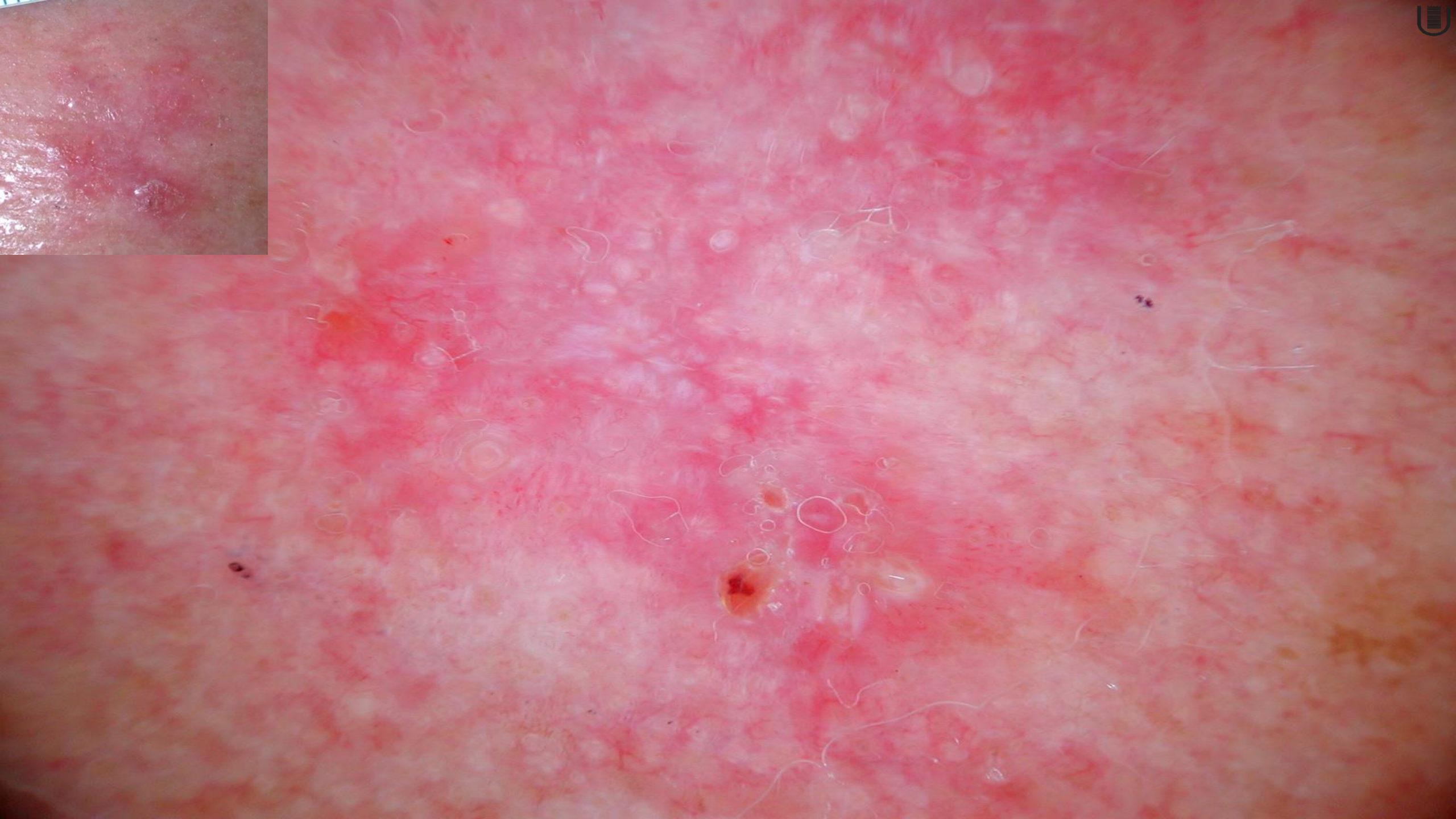

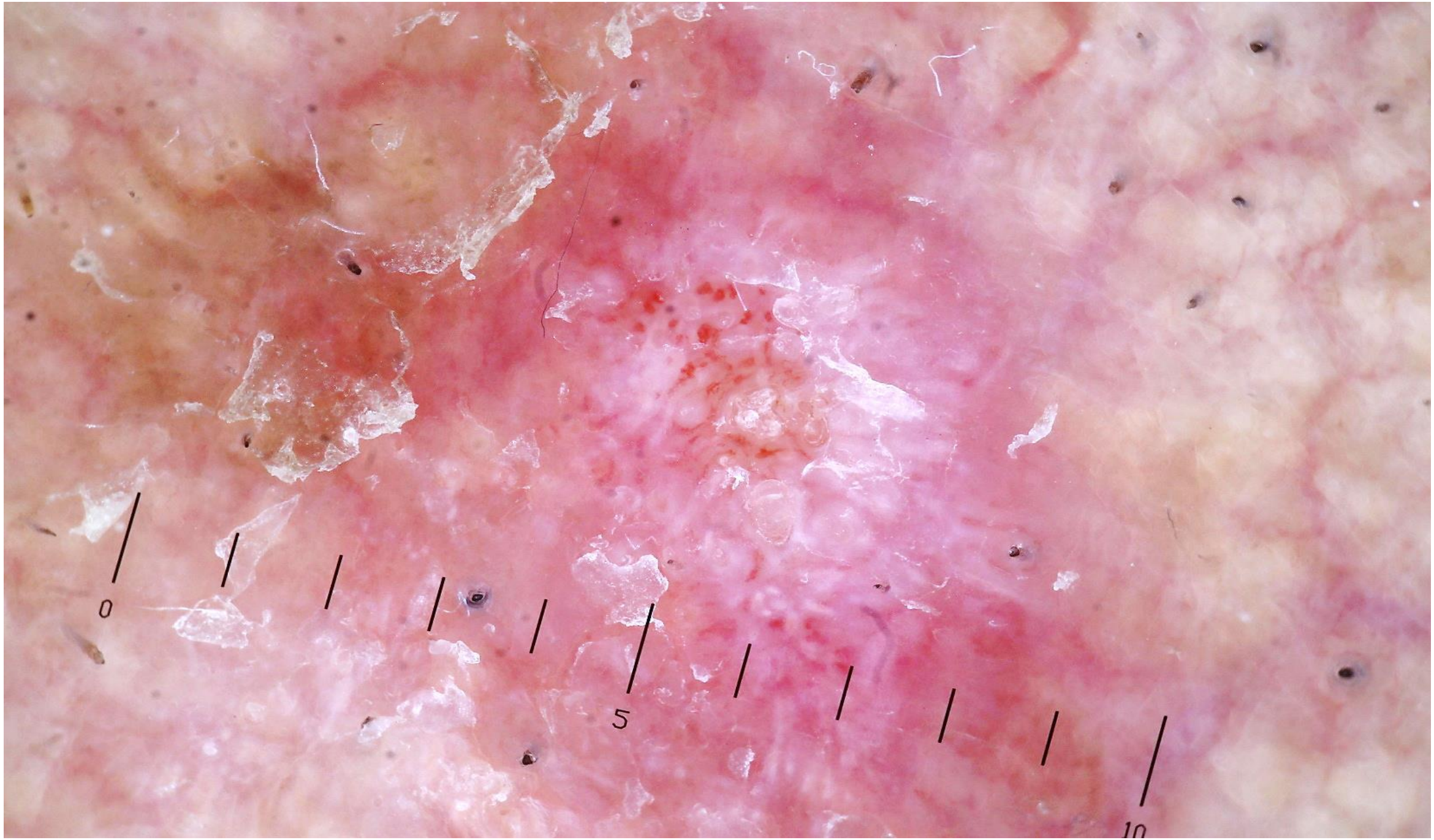
0
5
10

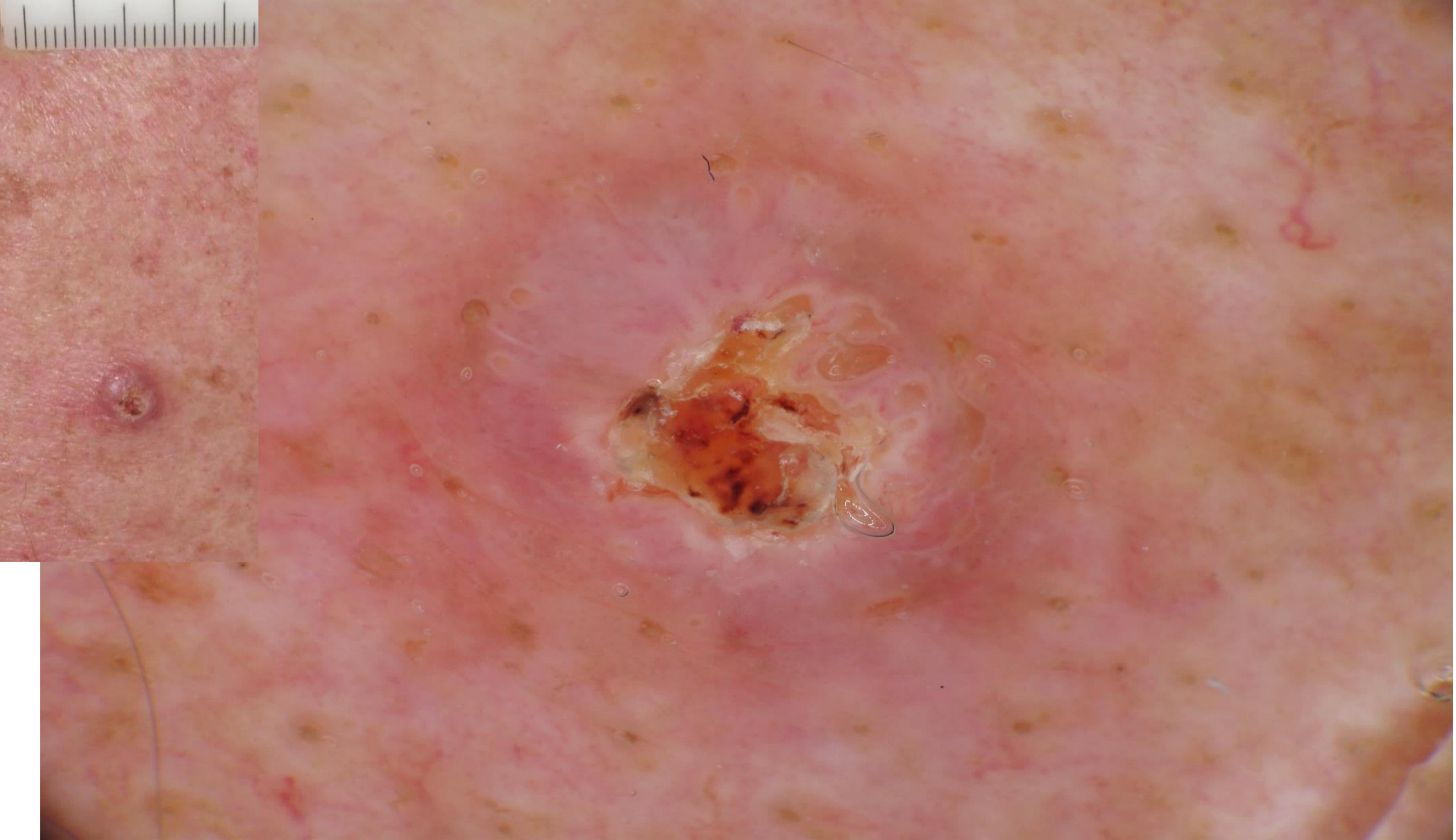

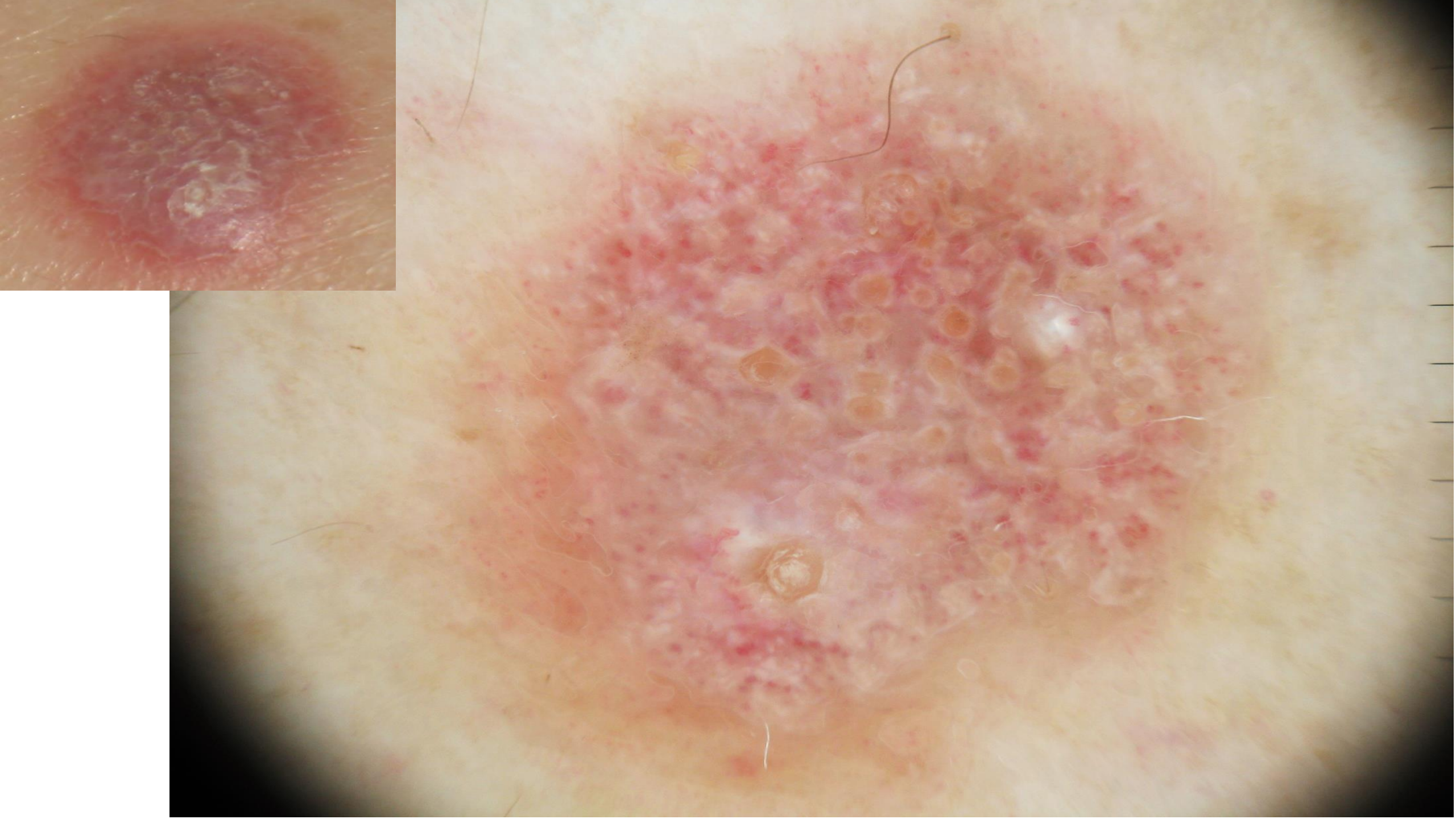

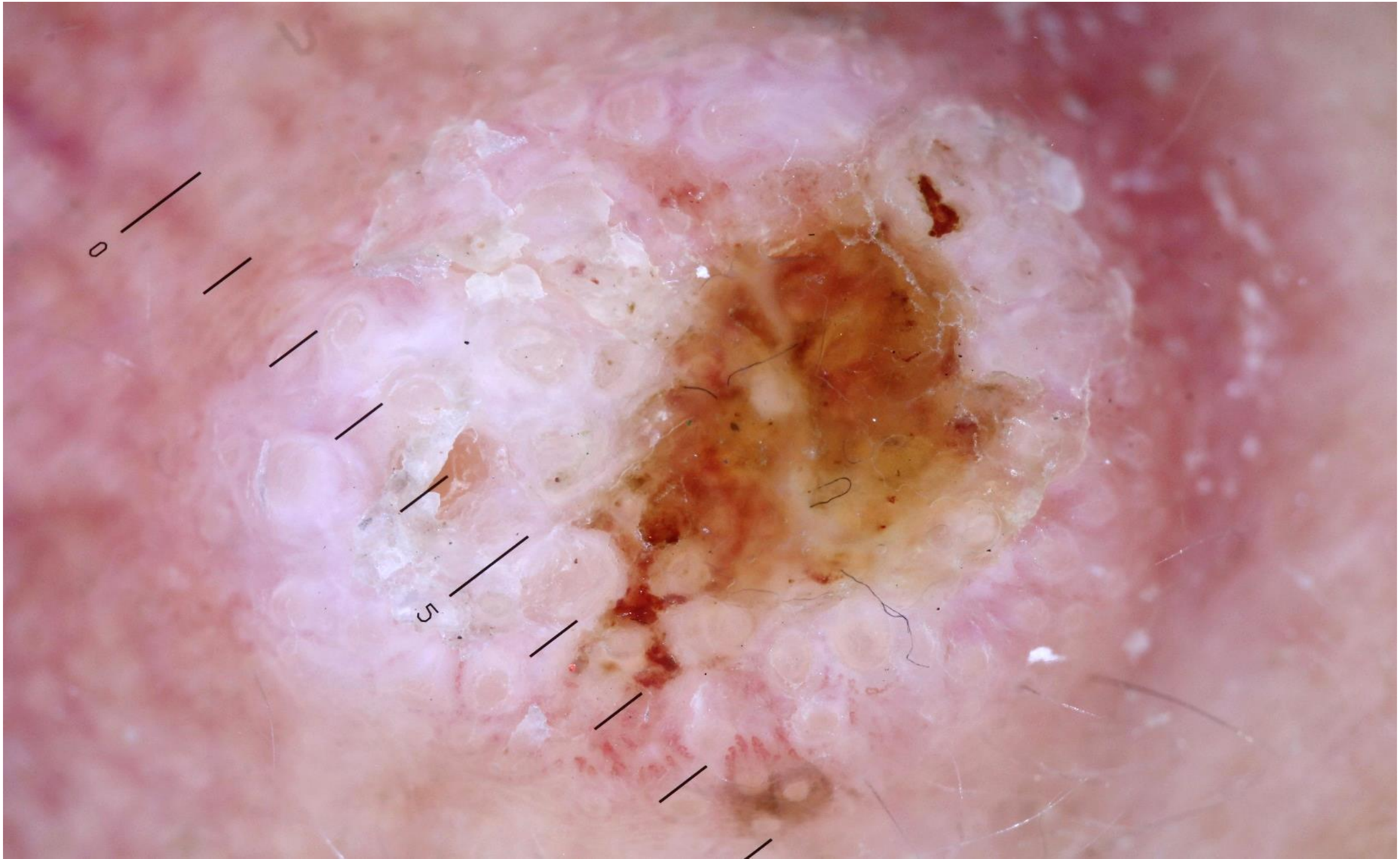
0
5

DERMATOLOGICAL SURGERY AND LASERS

BJD
British Journal of Dermatology

The clinical and dermoscopic features of invasive cutaneous squamous cell carcinoma depend on the histopathological grade of differentiation

A. Lallas,[1] J. Pyne,[2] A. Kyrgidis,[1] S. Andreani,[3] G. Argenziano,[1] A. Cavaller,[4] J. Giacomel,[5] C. Longo,[1] A. Malvestiti,[6] E. Moscarella,[1] S. Piana,[7] F. Specchio,[8] R. Hofmann-Wellenhof[9] and I. Zalaudek[9]

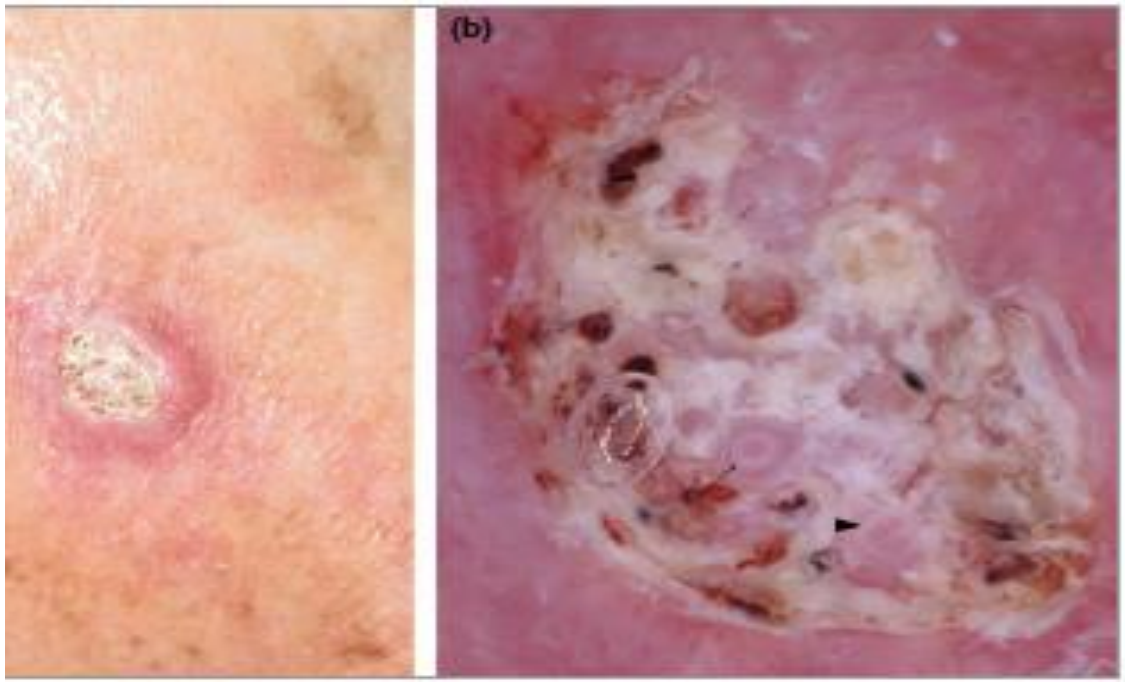

Well-differentiated SCC

Poorly-differentiated SCC

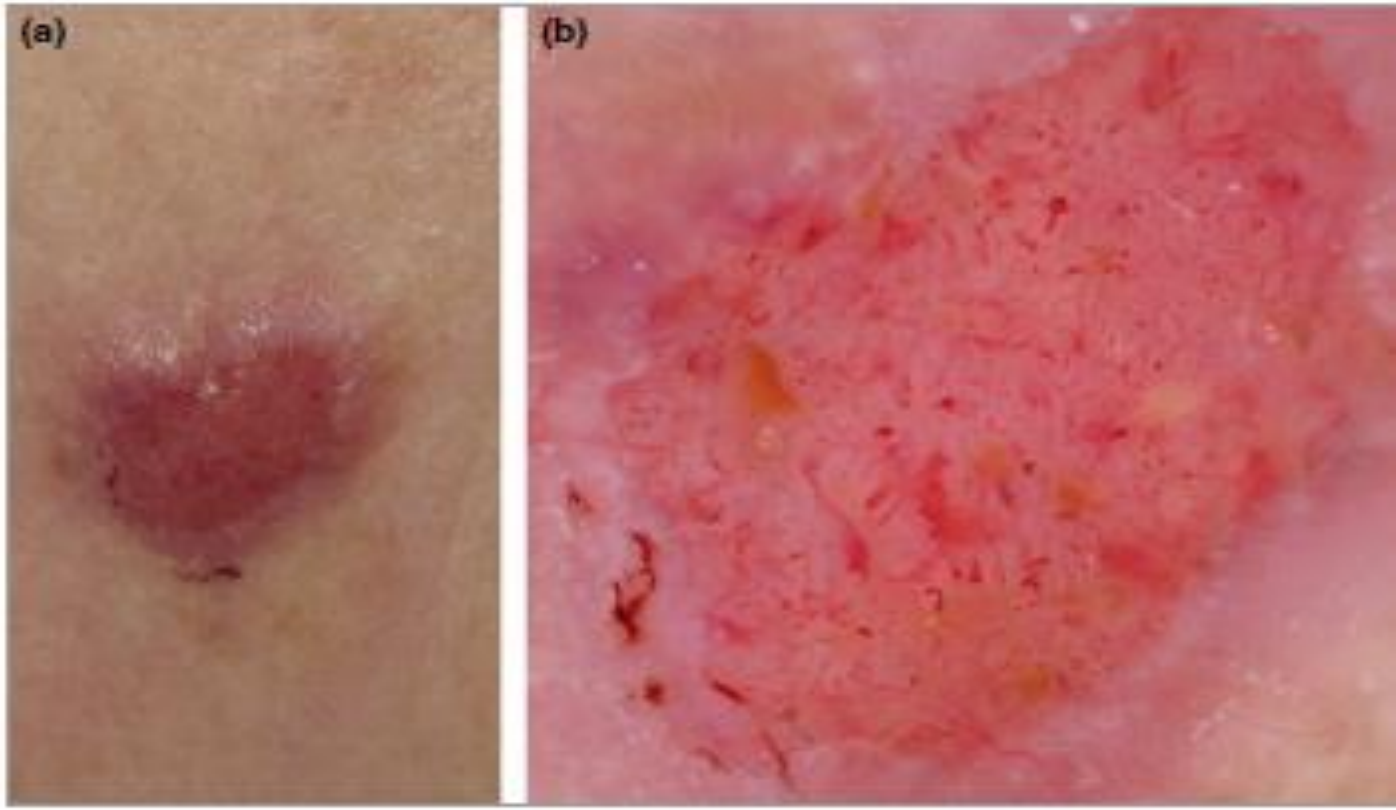

British Journal of Dermatology (2015) 172, pp1308–1315

DERMATOLOGICAL SURGERY AND LASERS
BJD
British Journal of Dermatology

The clinical and dermoscopic features of invasive cutaneous squamous cell carcinoma depend on the histopathological grade of differentiation

- Well-moderately differentiated:
  - Predominant WHITE color

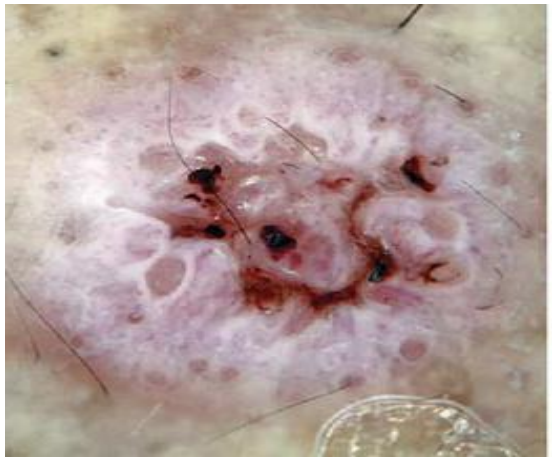

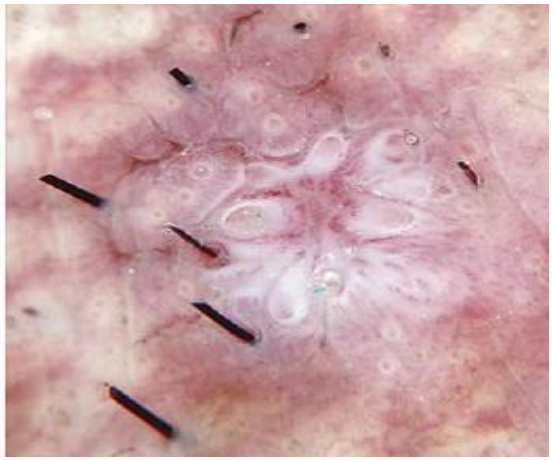

- Scales/keratin
- White circles
- White halos
- White structureless areas

Poorly differentiated:

Predominant **RED** color

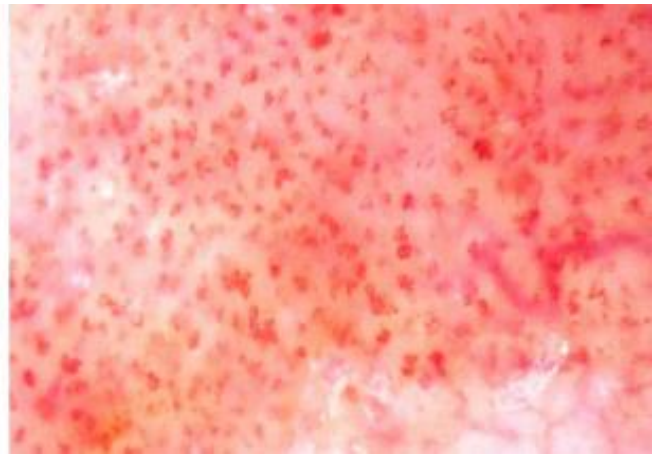

- >50% vascularity
- Vessel (diffuse distribution)
- Bleeding

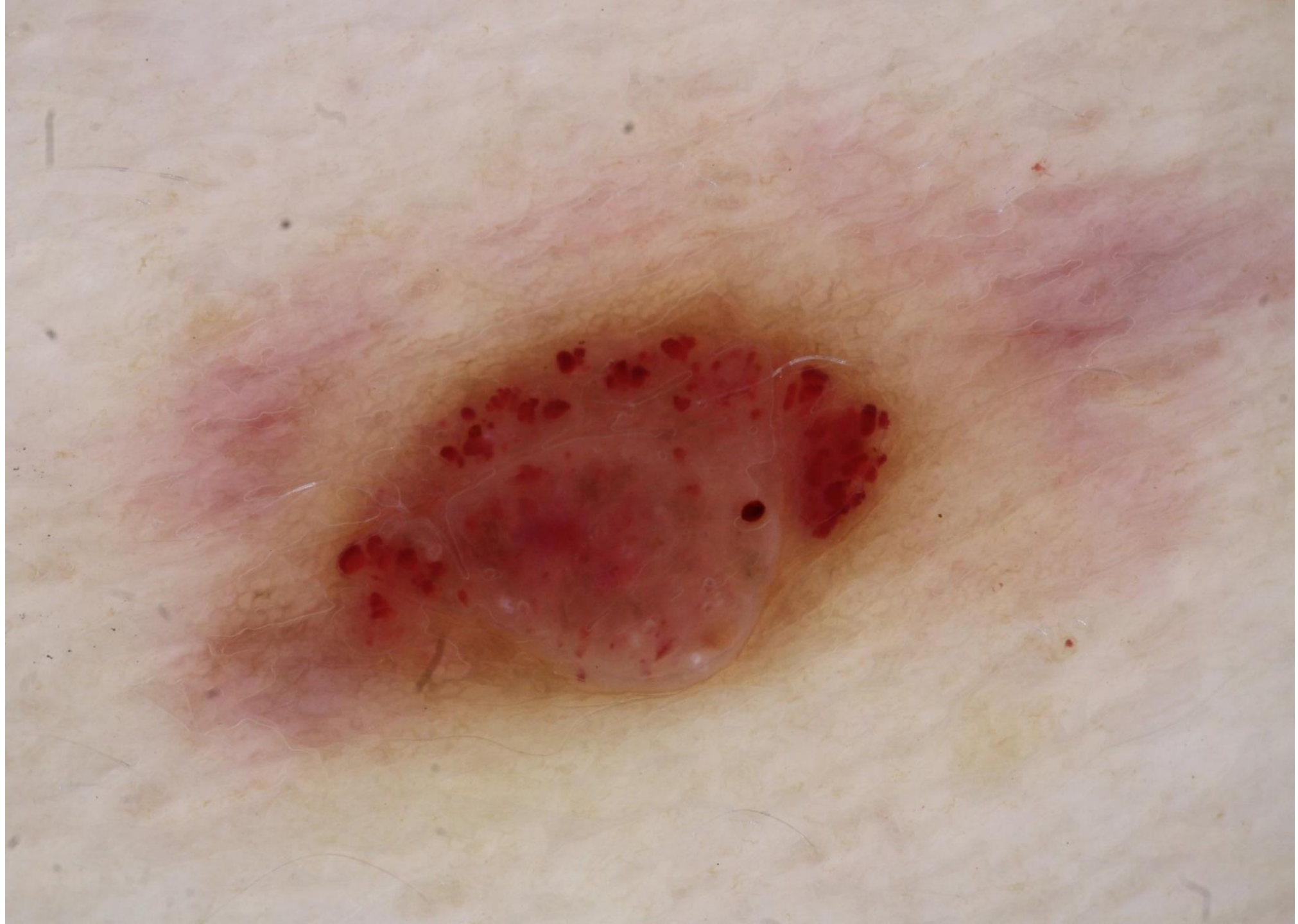

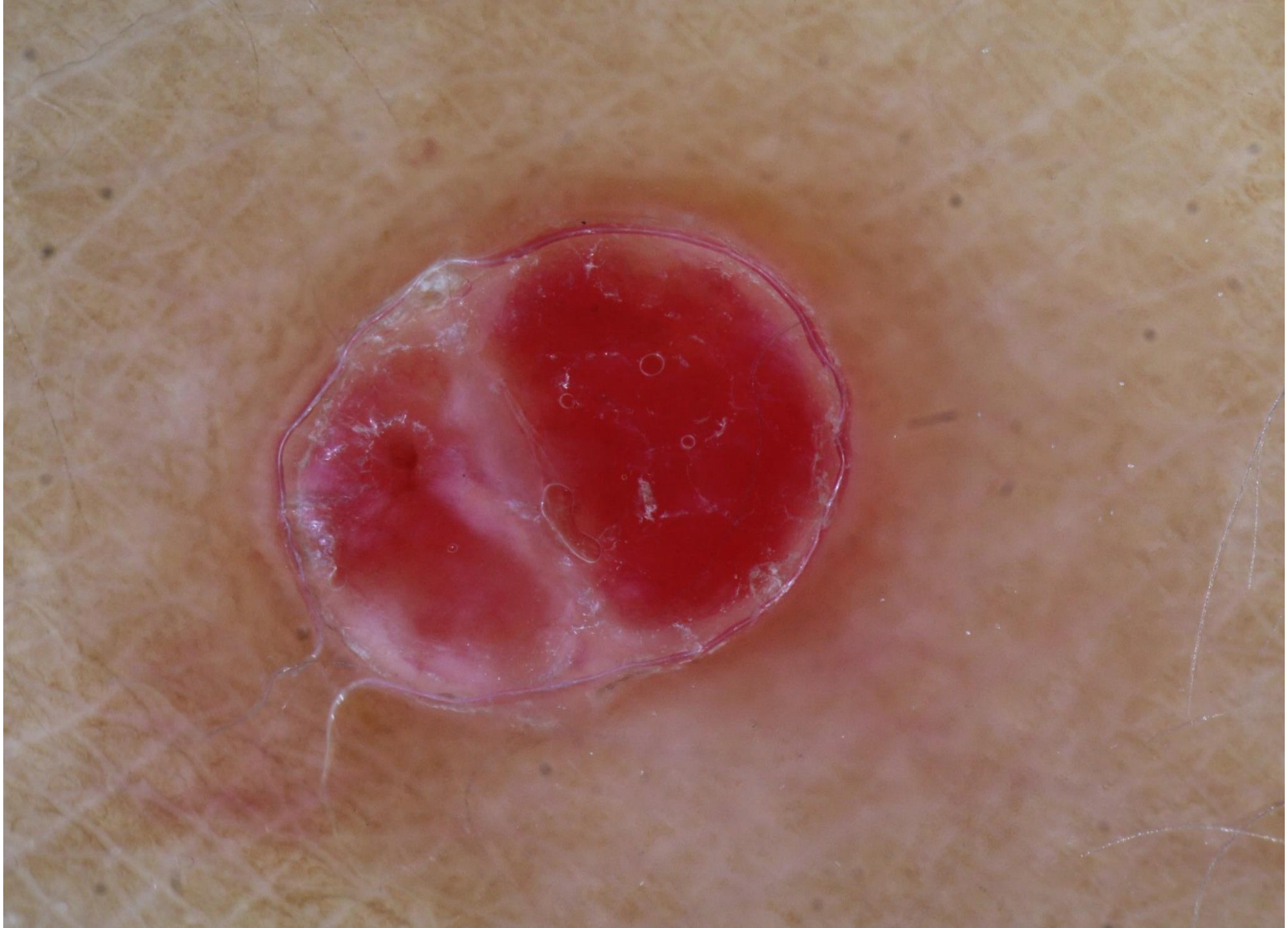

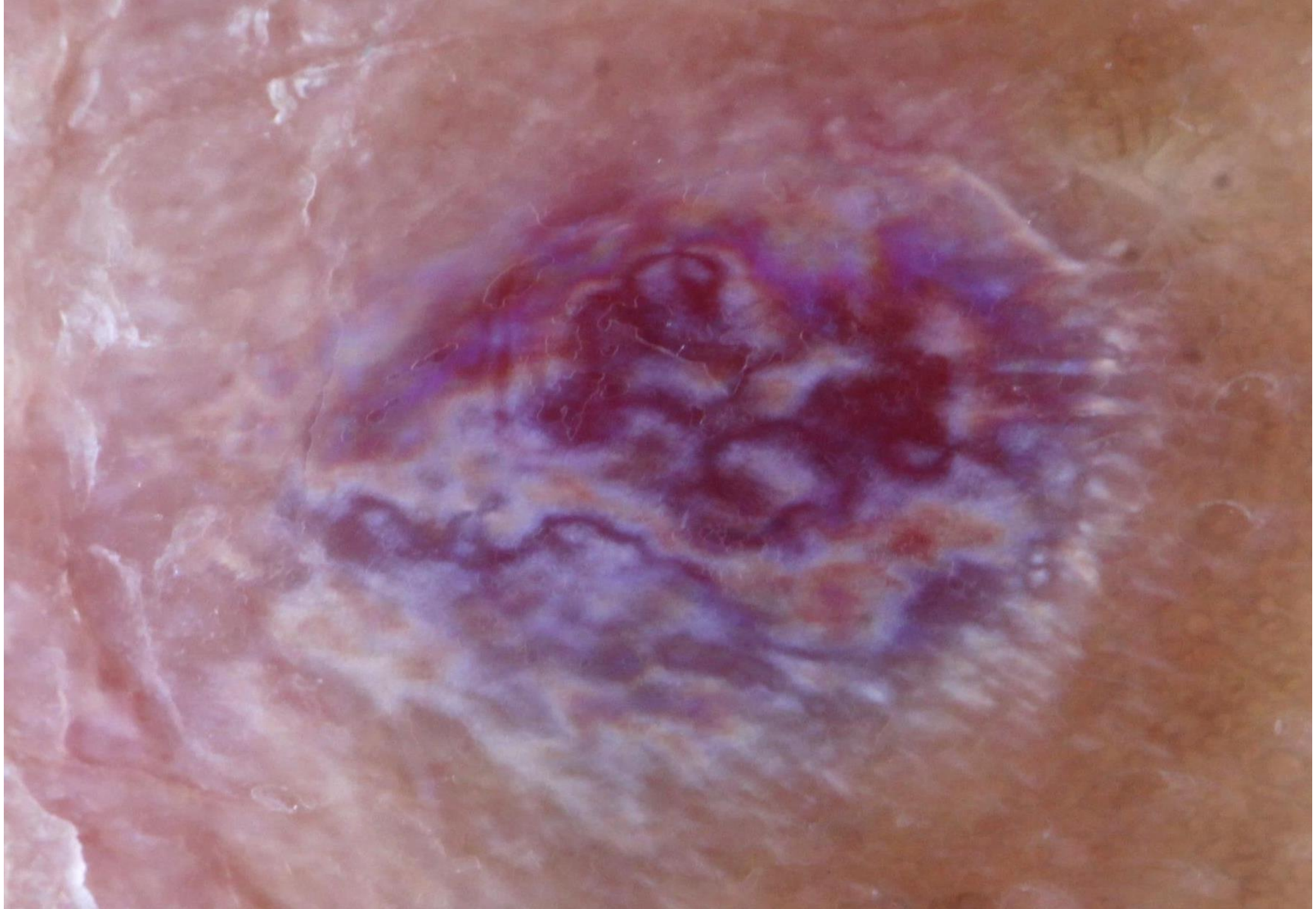

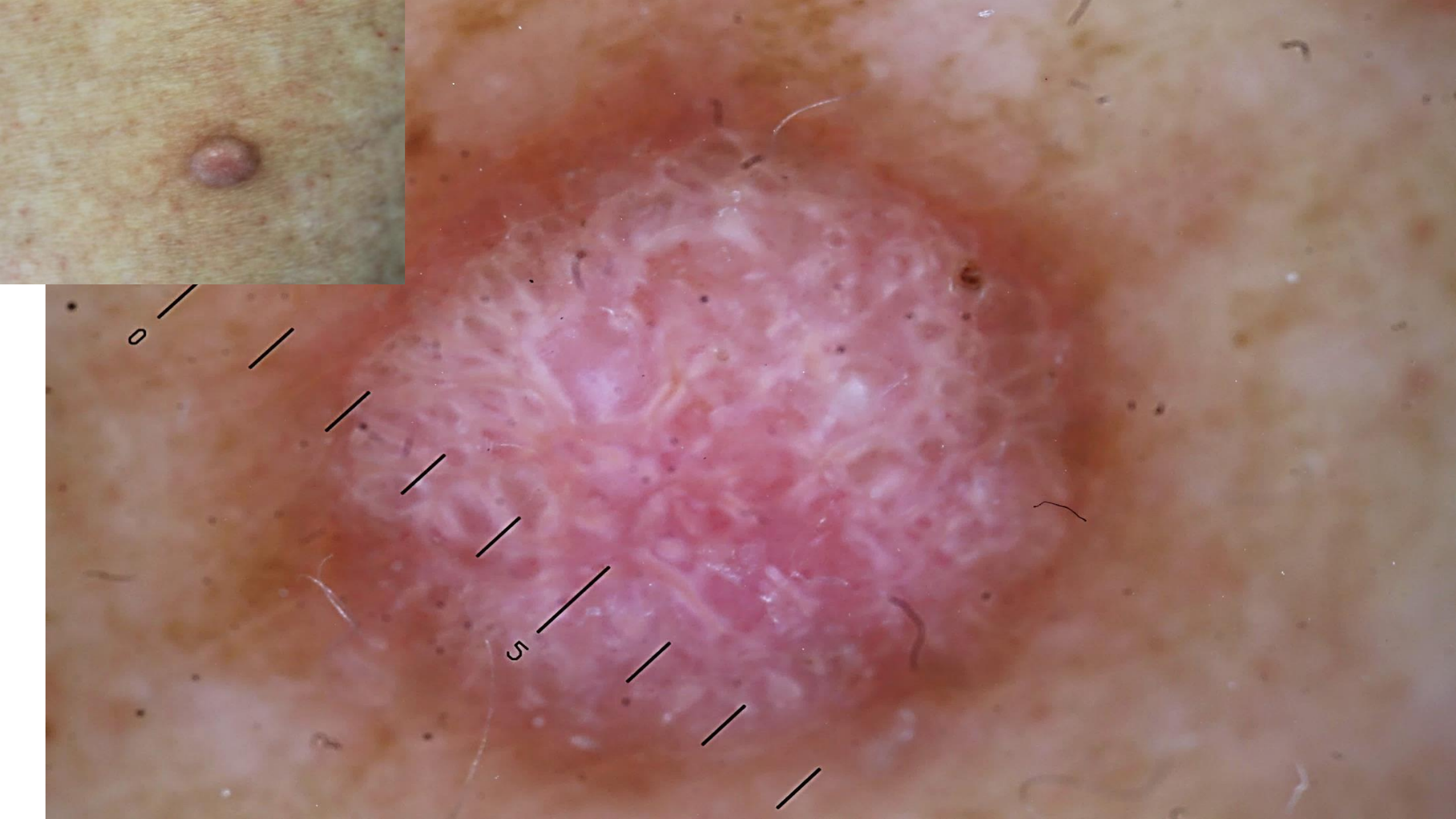
0
5

Ulcerazione

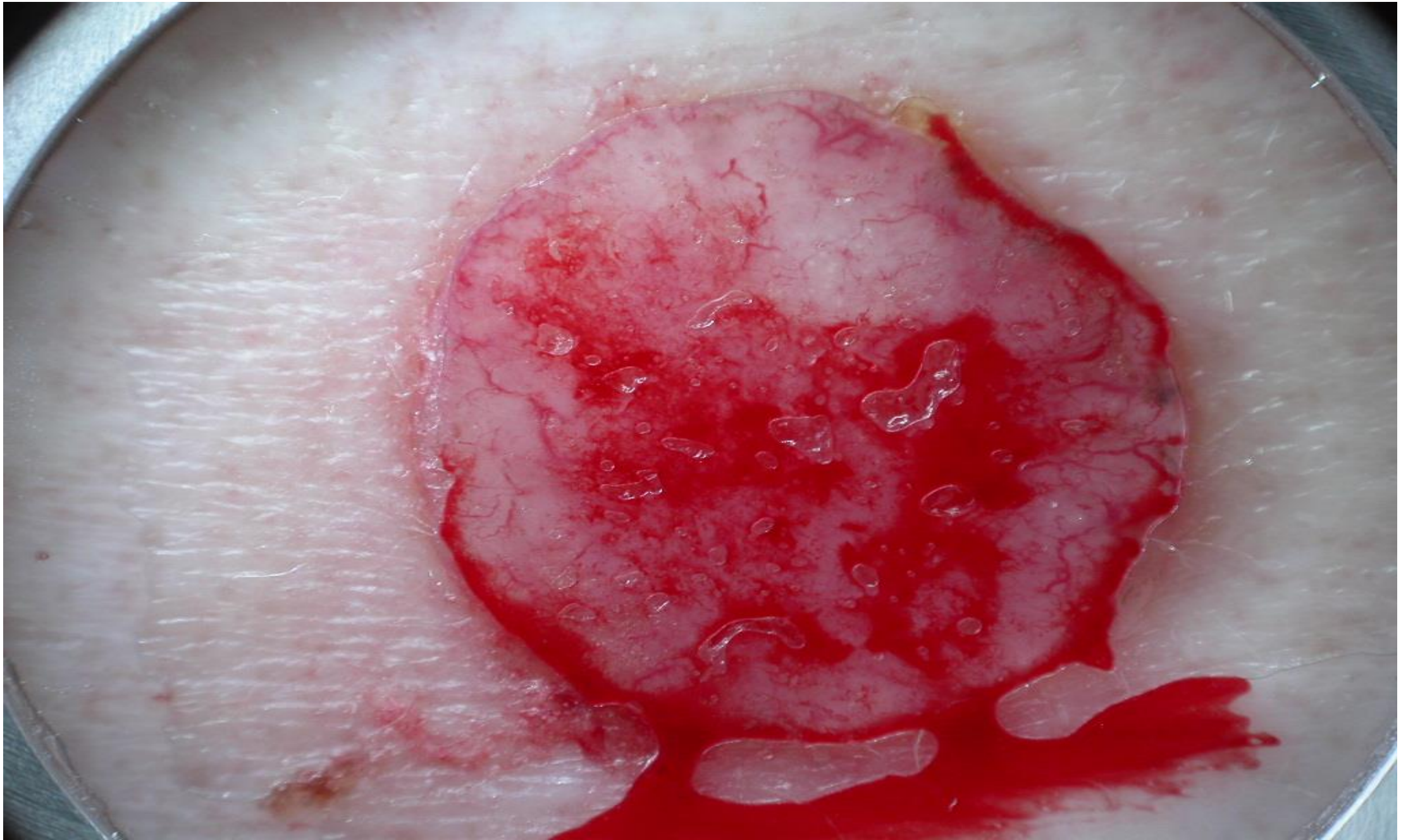

PREDICTION without PIGMENT

A Decision Algorithm for Non-Pigmented Skin Malignancy

Cliff Rosendahl[1], Alan Cameron[1], Agata Bulinska[1], Philipp Tschandl[2], Harald Kittler[2]

1. School of Medicine, The University of Queensland, Australia
2. Department of Dermatology and Venereology, Medical University of Vienna, Austria

The method presented here is a diagnostic tool, but no method, including this one, can be guaranteed to detect every malignancy In particular, any Elevated, Firm, Growing (EFG) lesion should be excised[1]

Prediction without Pigment - short version

Non-pigmented lesion

- Ulceration or white clues* present —— **Consider Biopsy (exclude malignancy)**
- Ulceration or white clues* not present — **Apply vessel pattern analysis[2] (see below)**

A polymorphous pattern including dots is strongly suspicious for melanoma
A clods-only pattern, and in raised lesions a centred or serpiginous pattern, should be benign. All other patterns must be assessed for malignancy.

A **clods-only pattern** must have no vessels within the (red/purple) clods. A centred pattern must have vessels centred in **skin-coloured** clods.

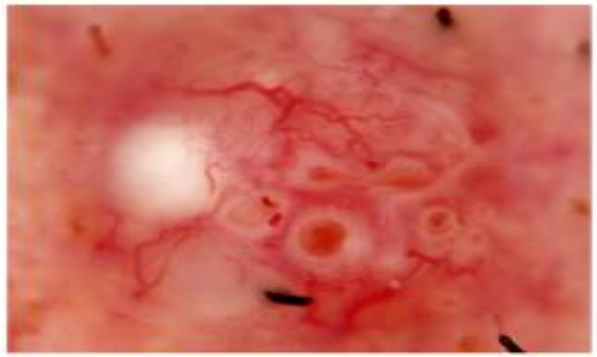
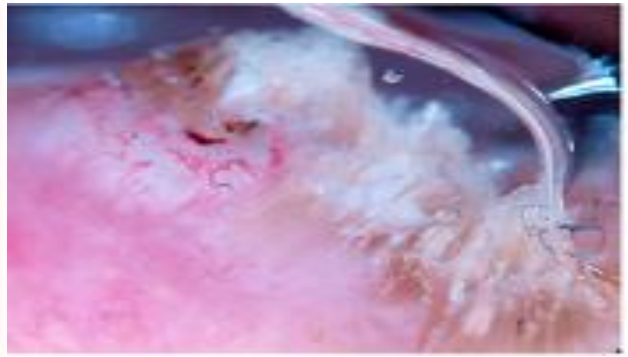
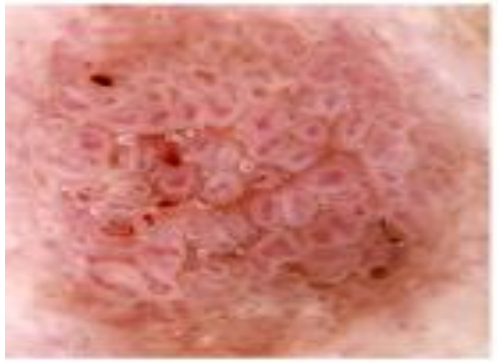
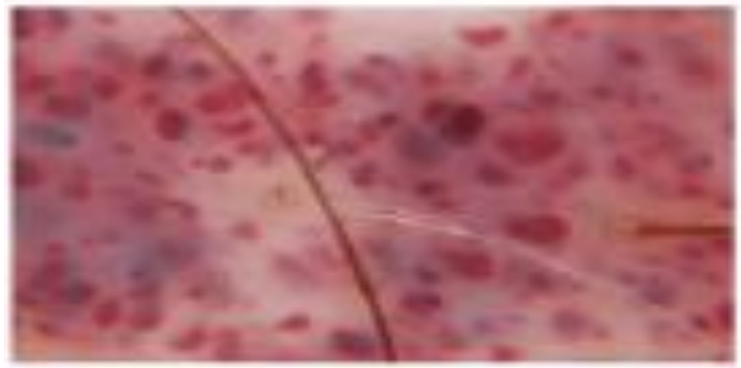

Dermatol Pract Concept 2013;4(1):9

Pink / featureless lesions

1. *Pattern Vascolari*
2. *Criteri per diagnosi specifiche*
3. *Residui di pigmento*

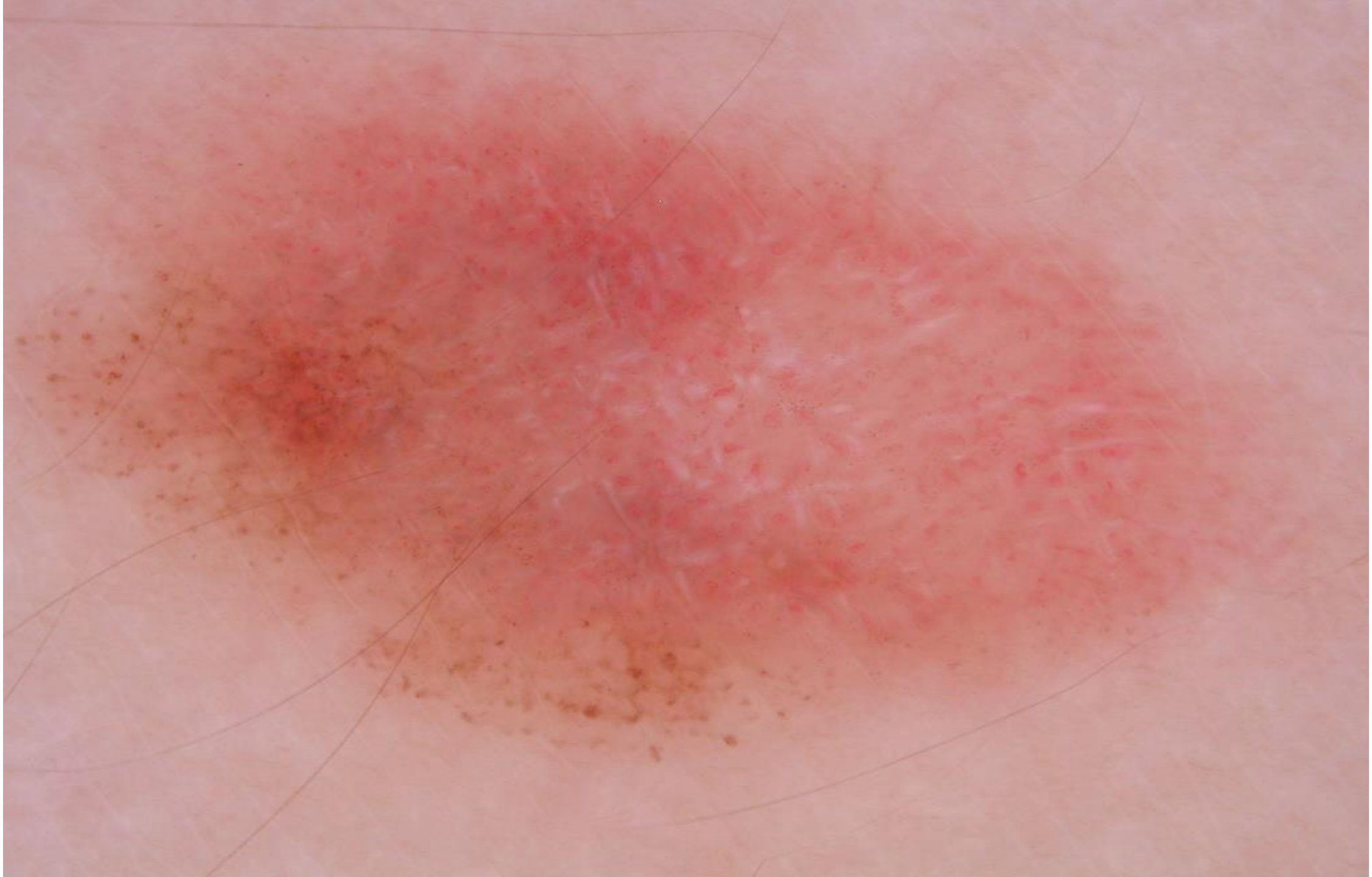

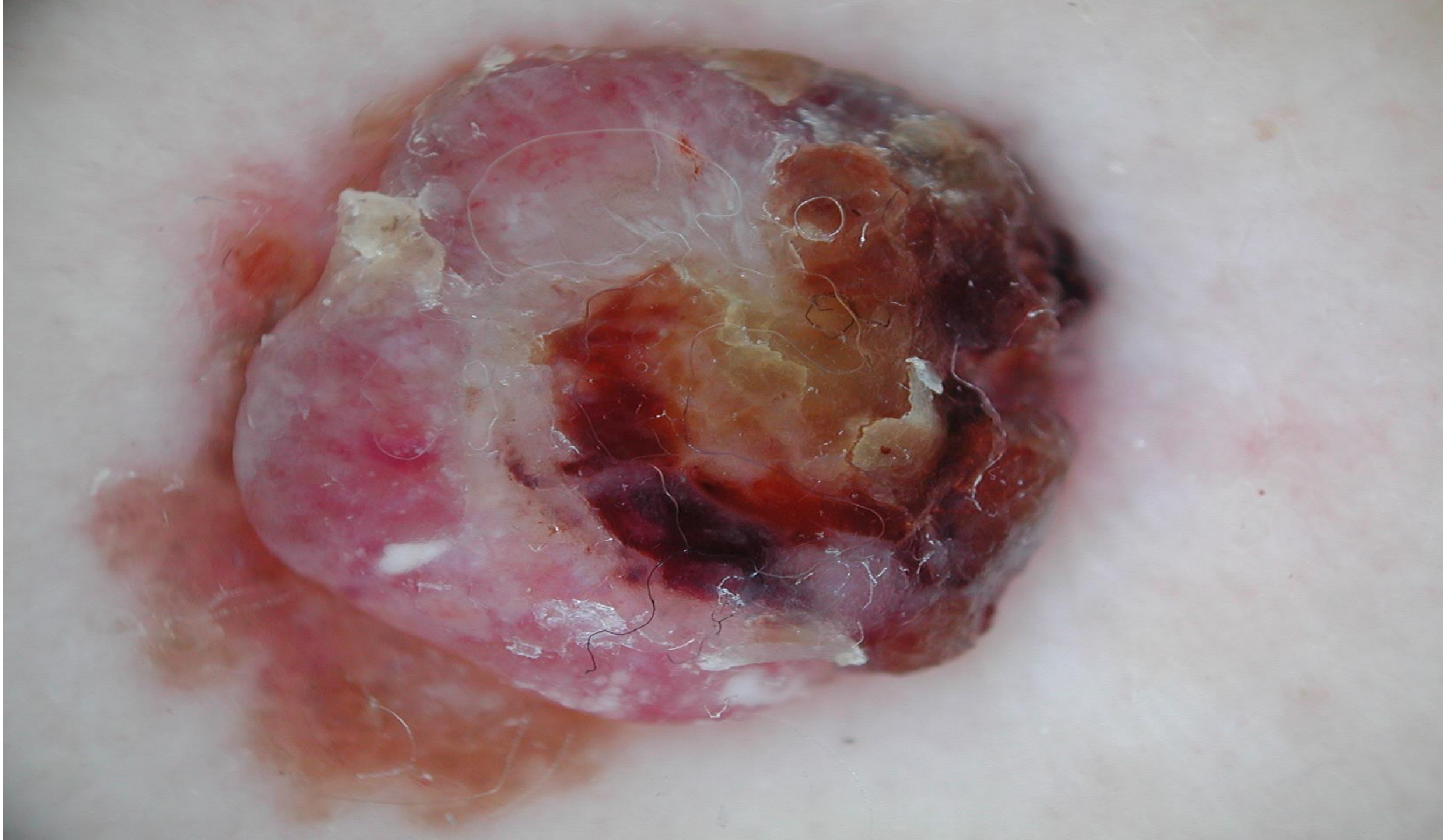

Pink / featureless lesions

1. *Pattern Vascolari*
2. *Criteri per diagnosi specifiche*
3. *Residui di pigmento*
4. *Pattern a luce polarizzata*

DERMATOLOGY PRACTICAL & CONCEPTUAL
www.derm101.com

Nodular melanoma: five consecutive cases in a general practice with polarized and non-polarized dermatoscopy and dermatopathology

Cliff Rosendahl[1], Matthew Hishon[1], Alan Cameron[1], Sarah Barksdale[2], David Weedon[2], Harald Kittler[3]

TABLE 2. Dermatoscopy features of the series of five consecutive nodular melanomas listed in Table 1.*

Case	Asymmetry	Blue/Black Structures	Gray/Blue Structures	Lines white (non-polarized)	Lines white polarizing specific	Polymorphous vessels
1	yes	no	no	yes	yes	yes
2	no	yes	yes	yes	yes	yes
3	yes	no	yes	no	yes	yes
4	yes	yes	yes	no	yes	no
5	no	yes	yes	no	no	no

Nodular melanoma: polarizing-specific white lines

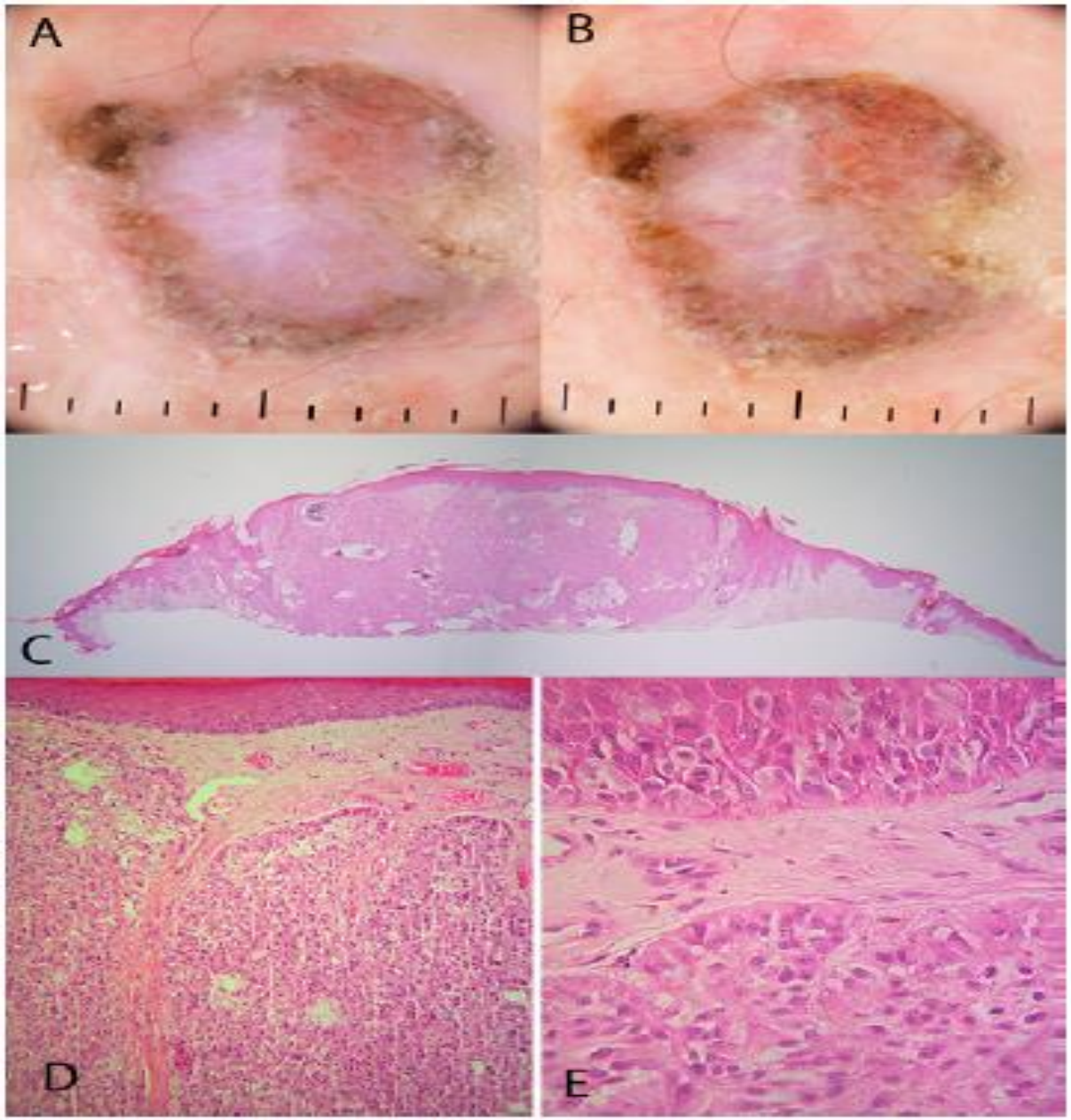

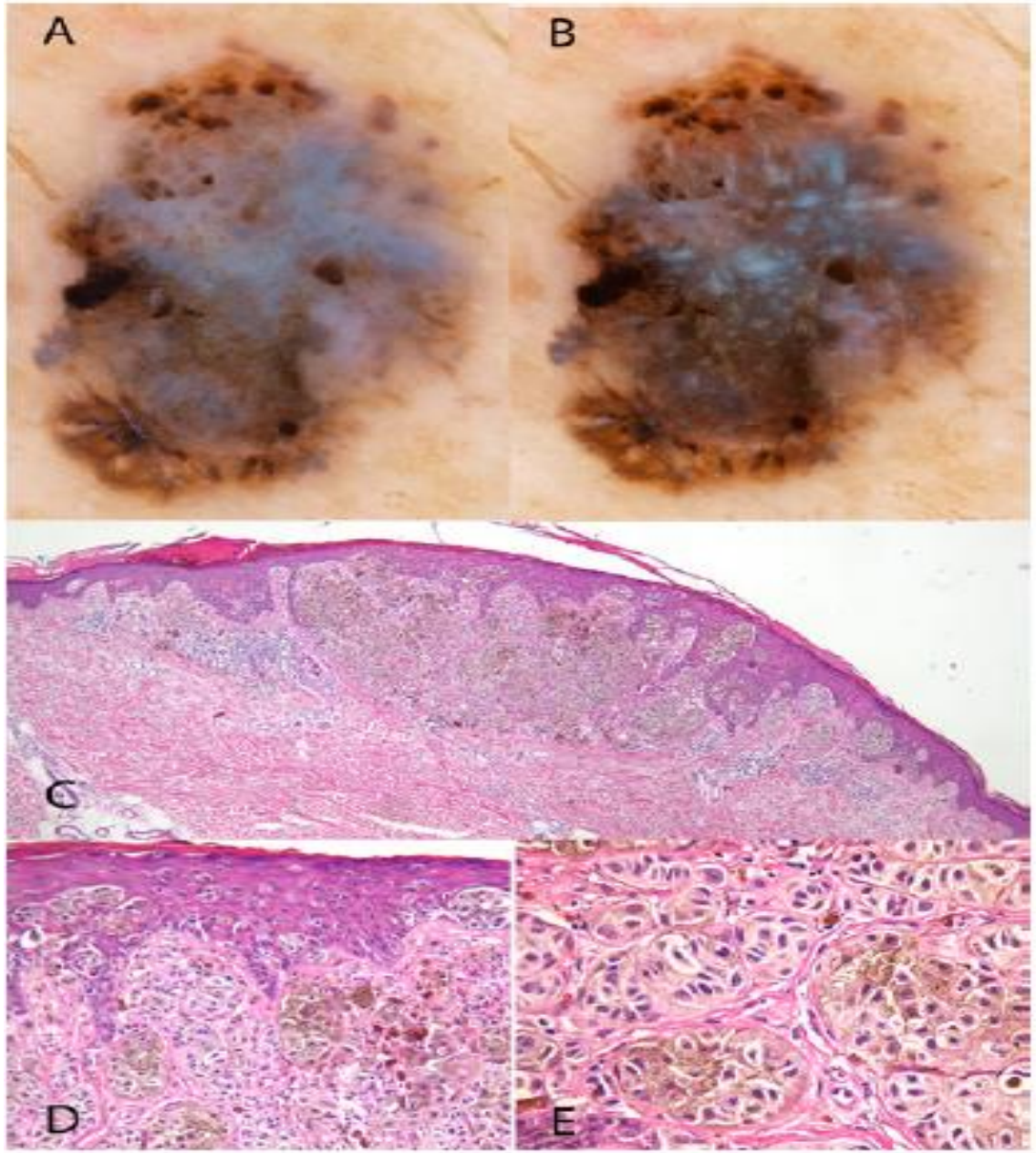

Nodular melanoma: polarizing-specific white lines

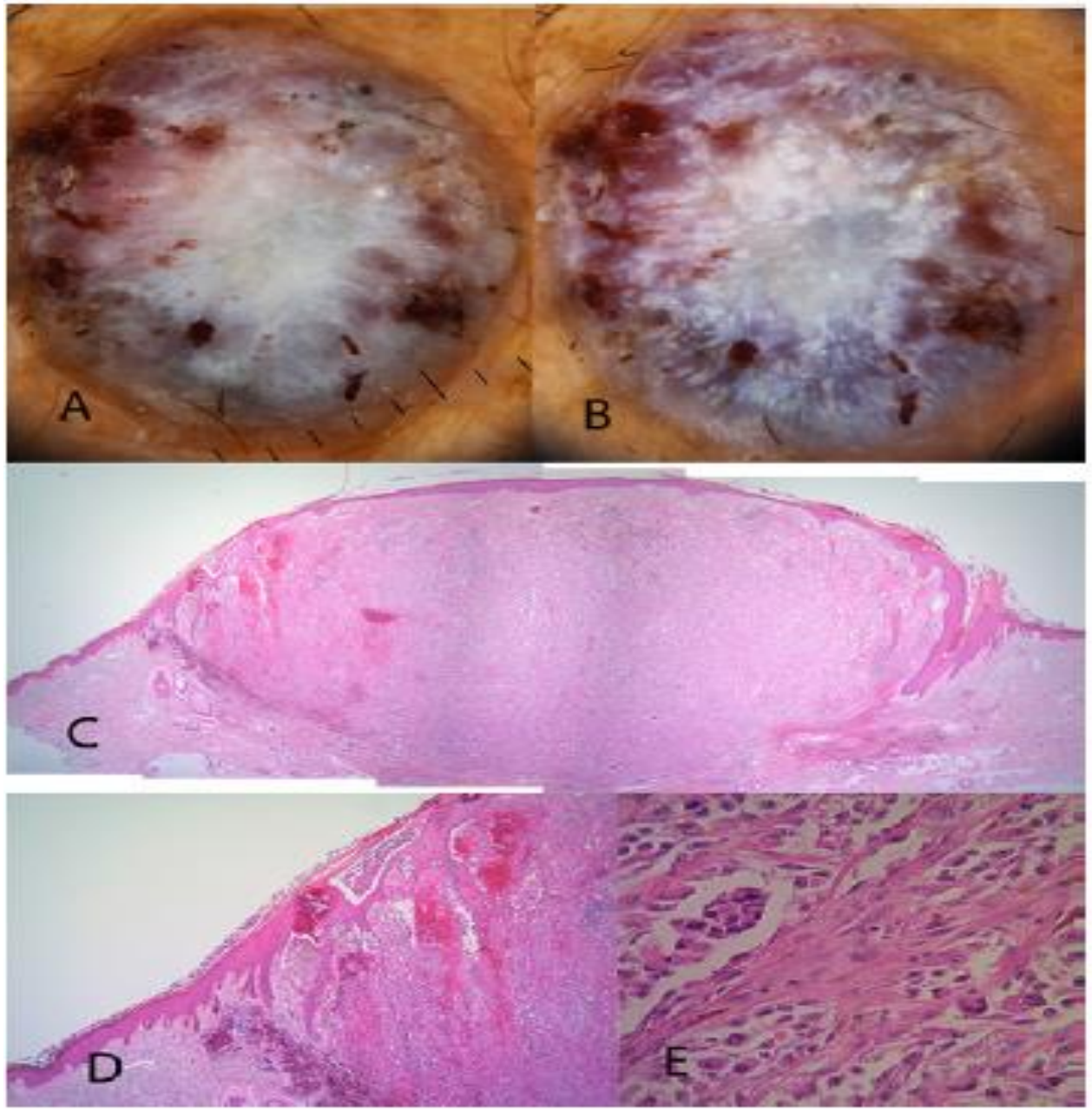

- may be dermoscopically symmetrical
- clues to melanoma are frequently present:
  - ✓ gray/blue color
  - ✓ polarizing-specific white lines
- clue of ***polarizing-specific white lines*** should lead to excision unless a confident specific benign diagnosis (e.g. dermatofibroma) can be made on historic and clinical grounds

Shiny-white streaks: definizione

- *"Shiny-white areas which often have a stellate or streak-like appearance"* (Benvenuto-Andrade, 2007)
- *"shiny, bright white, linear streaks*
- *often oriented parallel to each other or in an orthogonal fashion"*
- have been also termed *"chrysalis structures"* (Marghoob, 2009)

Marghoob AA. et al. *Arch Dermatol* 2009;145:618.

⟶ Shiny-white streaks ⟵

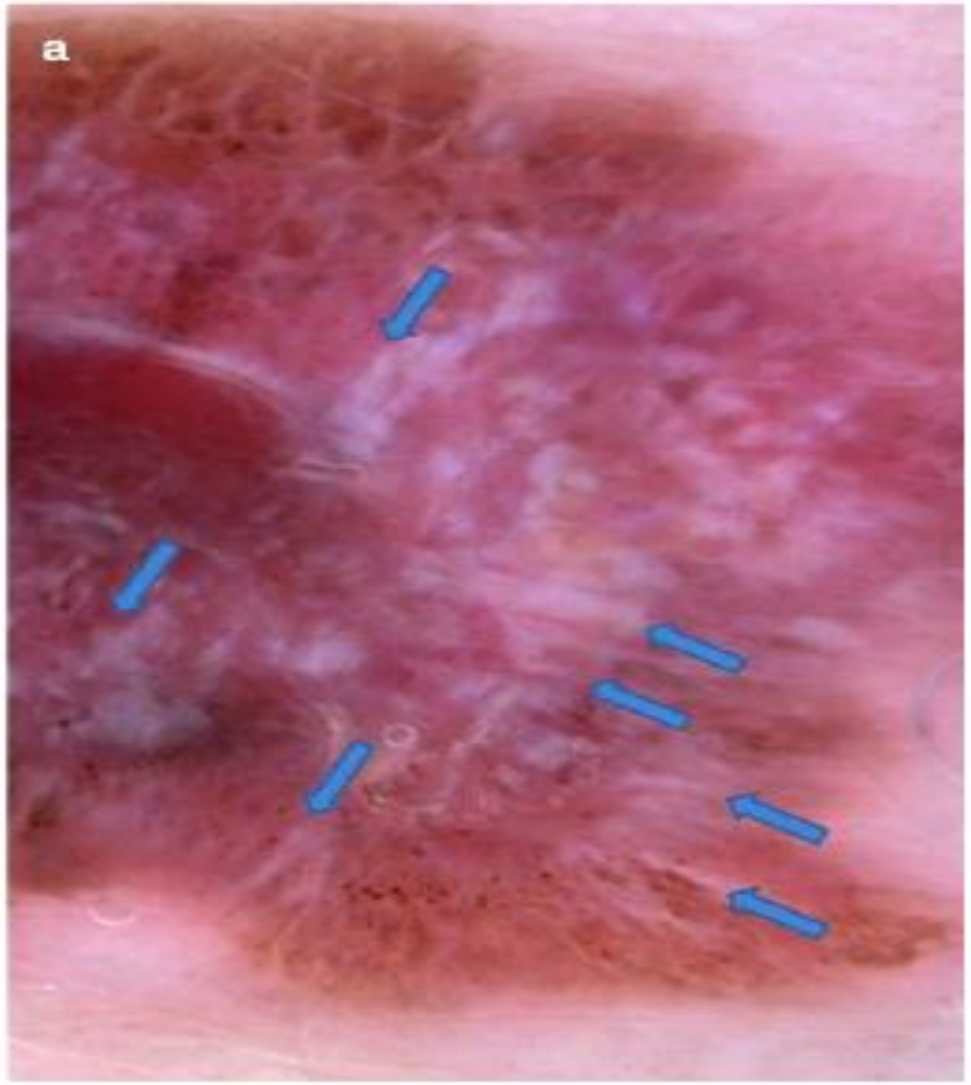

Dermoscopia
a luce polarizzata

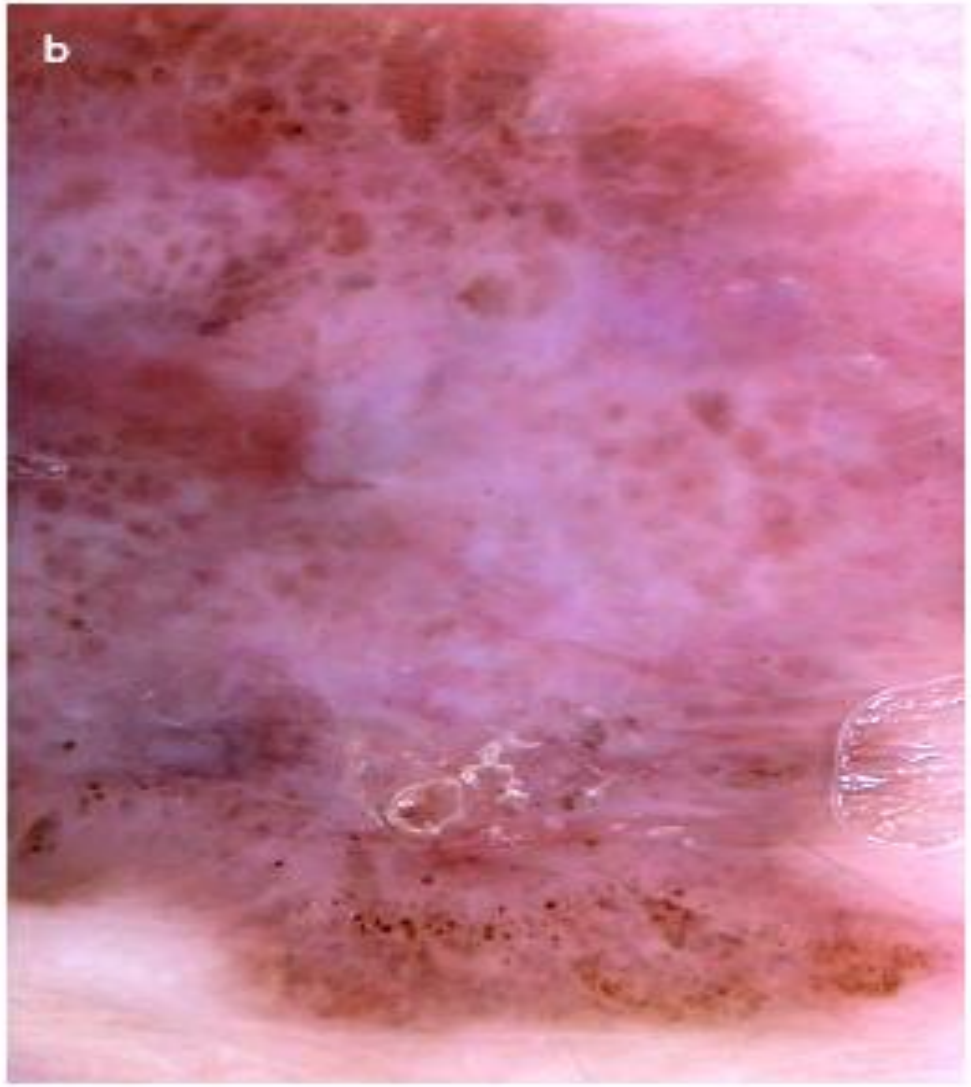

Dermoscopia
a luce non polarizzata

Di Stefani A. et al. *Australas J Dermatol* 2010;51:295-8.

“Crisalide” è un termine improprio!

- Stadio di pupa (o crisalide)della farfalla

- Bozzolo della tarma della cera (della larva)

- Bozzolo della farfalla “del cactus”

Chrysalis = Shiny white streaks
= Crystalline structures

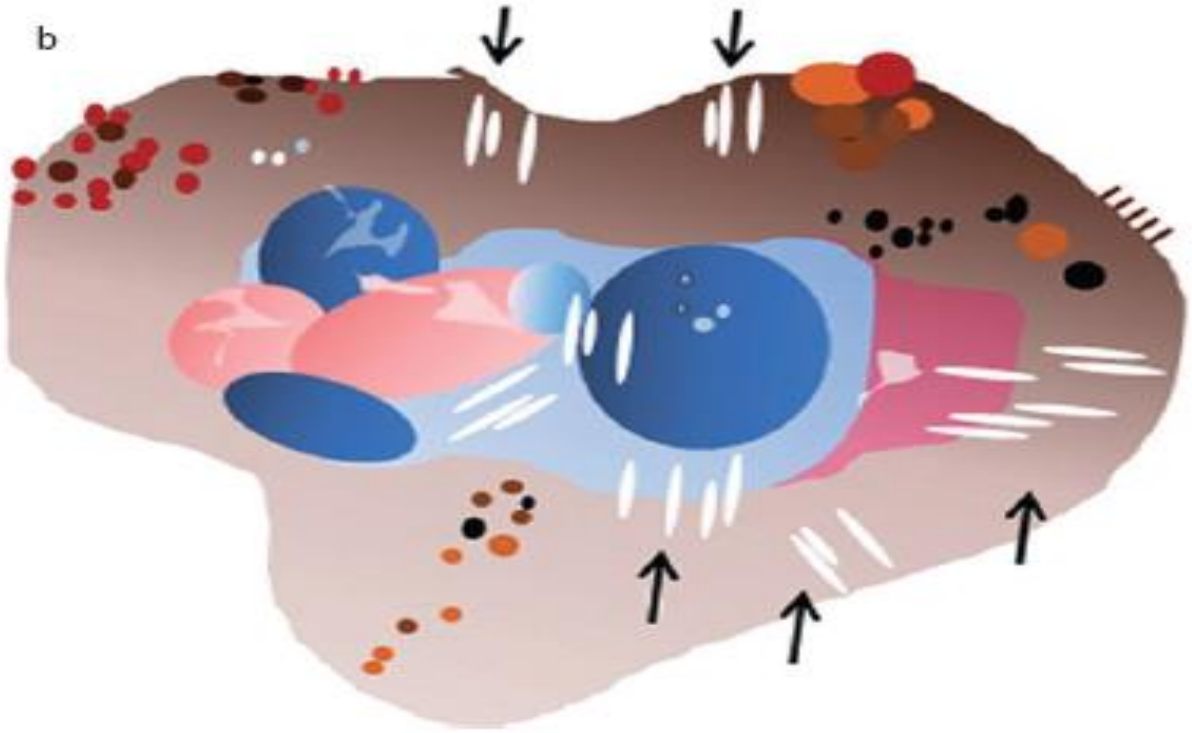

Di Stefani A. et al. *Australas J Dermatol* 2010;51:295-8.

Le SWS vanno distinte dal reticolo invertito

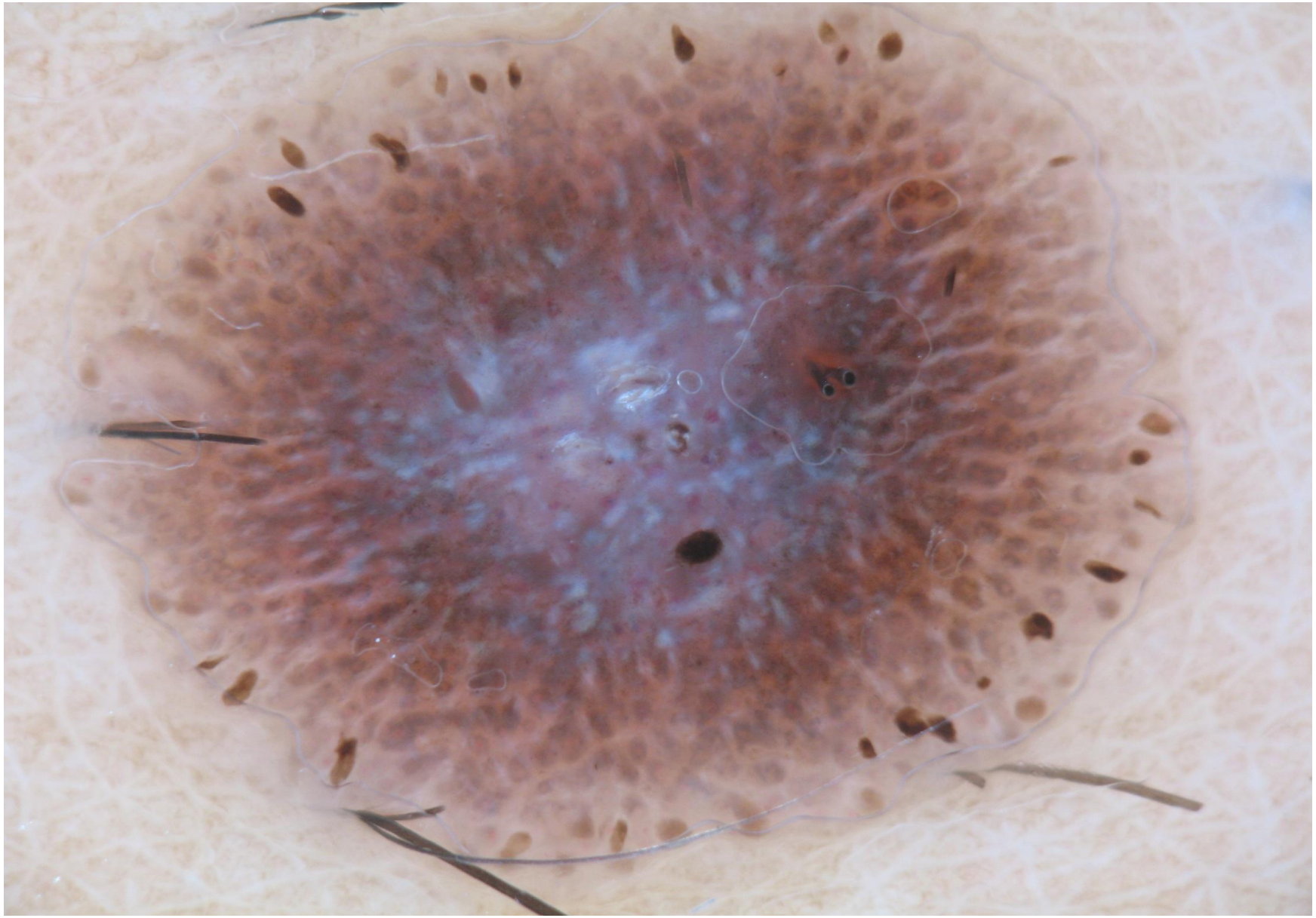

Depigmentazione reticolare, con aspetto a rete, ad andamento serpiginoso

Shiny-white streaks: correlato istopatologico

- Le SWS corrispondono alla interazione della luce polarizzata con il collagene birifrangente nel derma papillare
- Espressione di bFGF nel fronte di invasione del melanoma nel derma papillare (interazione stroma-malanoma)
- bFGF induce sintesi di collagene di tipo I

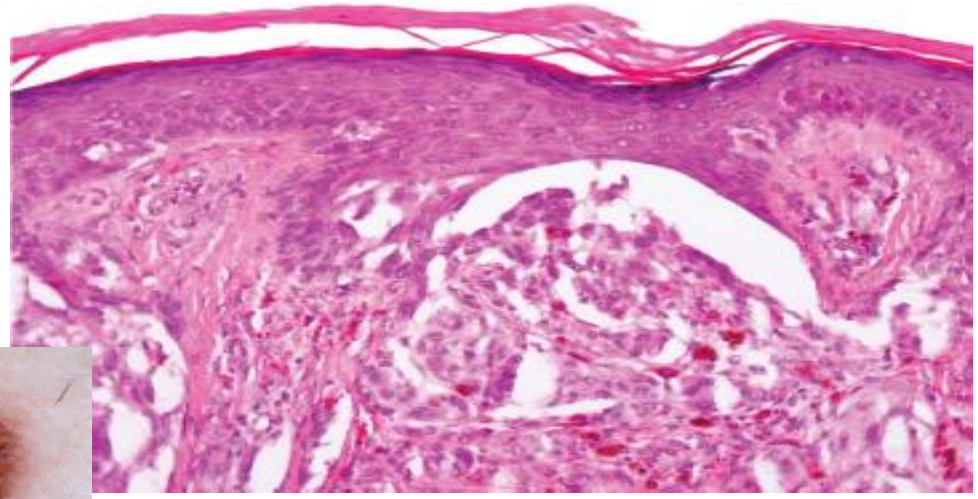

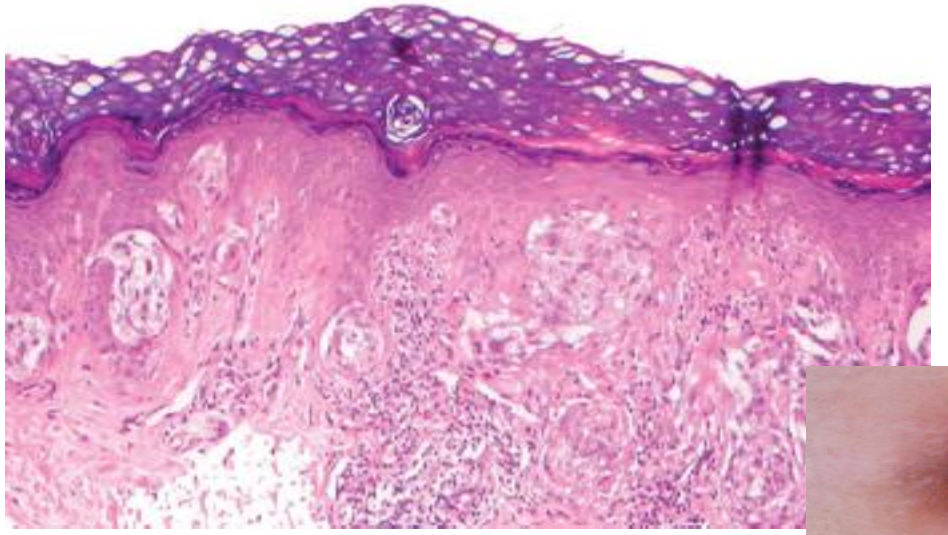

Australasian Journal of Dermatology

Australasian Journal of Dermatology (2010) 51, 295–298 doi: 10.1111/j.1440-0960.2010.00672.x

Shiny white streaks: An additional dermoscopic finding in melanomas viewed using contact polarised dermoscopy

Alessandro Di Stefani,[1] Terri M. Campbell,[2] Josep Malvehy,[3] Cesare Massone,[4] H Peter Soyer[2] and Rainer Hofmann-Wellenhof[4]

[1]Department of Dermatology, University of Rome 'Tor Vergata', Italy; [2]Dermatology Research Centre, The University of Queensland, School of Medicine, Princess Alexandra Hospital, Brisbane, Australia; [3]Dermatology Department, Hospital Clinic, Barcelona, Spain; and [4]Department of Dermatology, Medical University of Graz, Graz, Austria

- Obiettivo: studiare la frequenza delle SWS nelle lesioni melanocitarie
- Analisi retrospettiva di una serie consecutiva di:
- 400 Melanomi
- 400 Nevi (102/400 istologicamente confermati)

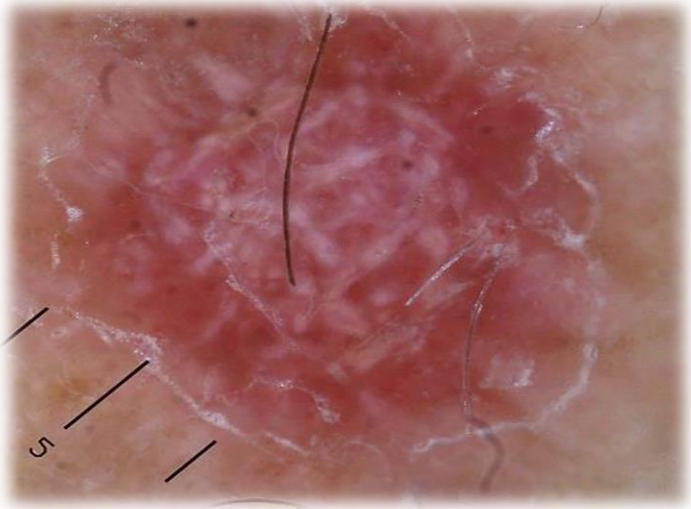

Di Stefani A. et al. *Australas J Dermatol* 2010;51:295-8.

SWS nelle lesioni melanocitiche: Risultati

- La presenza delle SWS è stata identificata nel:
- 31.0% (124/400) dei melanomi
- 1.3% (5/400) dei nevi (2 Spitz, 2 blu, 1 Clark)
- Differenza statisticamente significativa (*P < 0.05)*

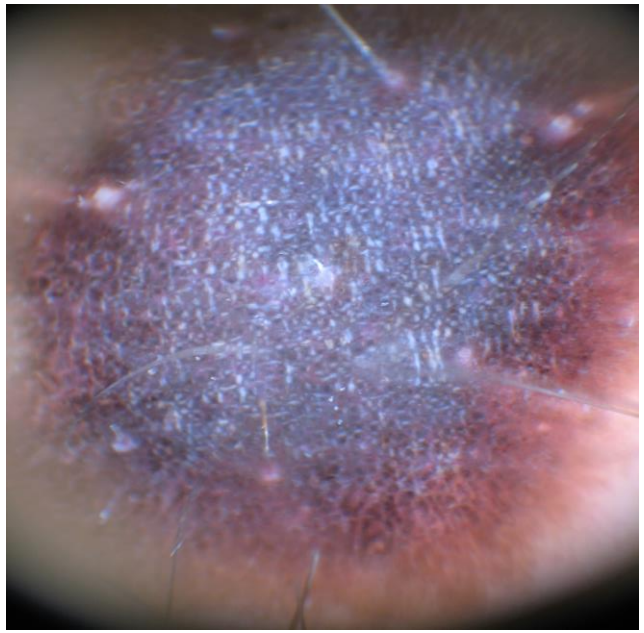

- 400 melanomi: Breslow medio di 0.87 mm
- 124 melanomi con SWS: Breslow medio di 1.27 mm
- 276 melanomi senza SWS: Breslow medio di 0.30 mm
- Differenza statisticamente significativa *(P < 0.05)*

Di Stefani A. et al. *Australas J Dermatol* 2010;51:295-8.

F 41 - coscia - Insorta da pochi mesi

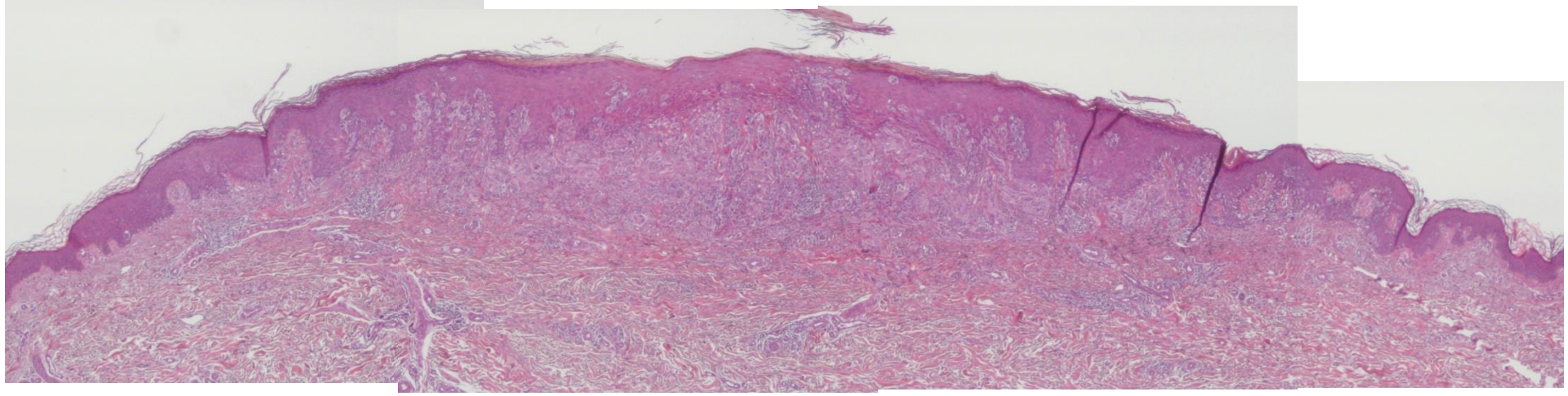

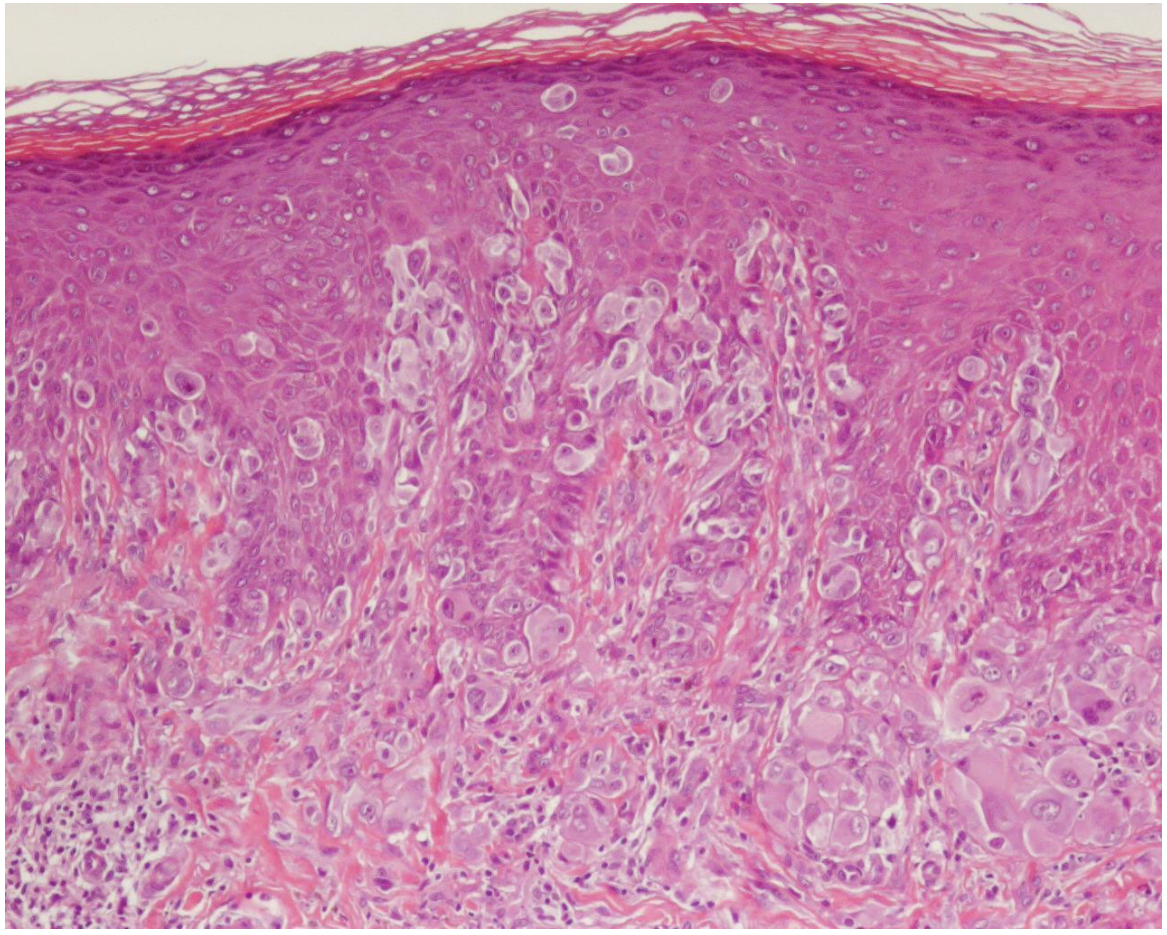

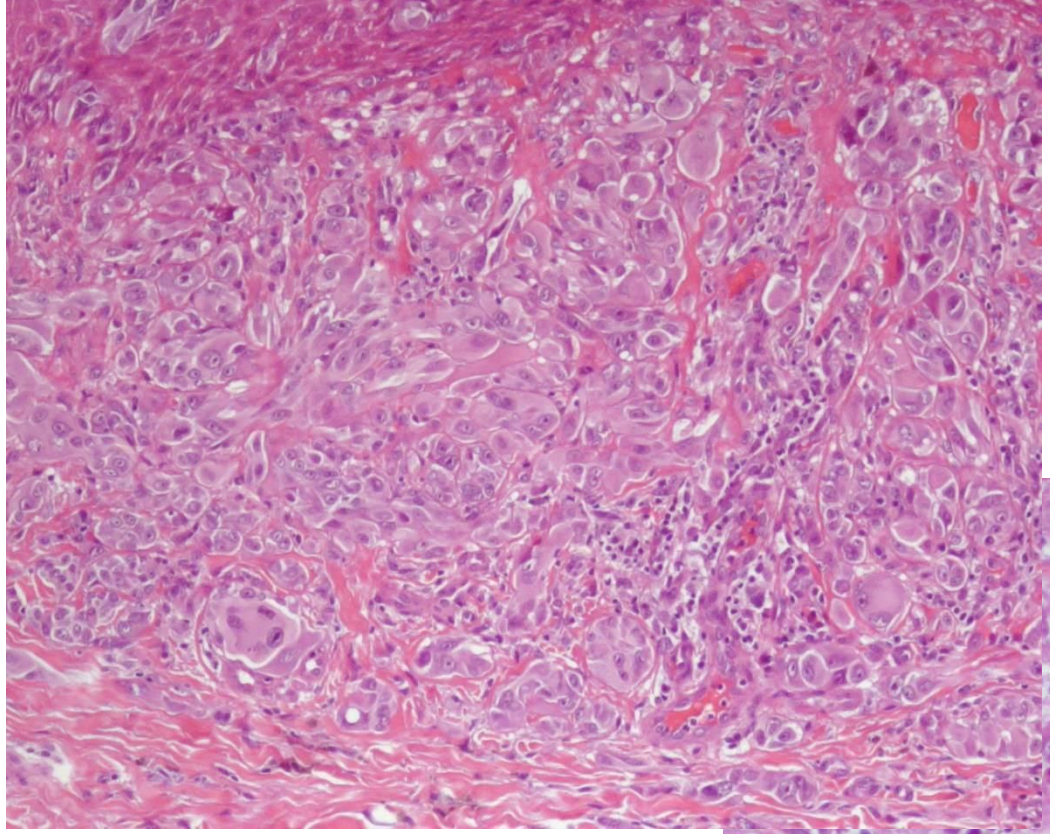

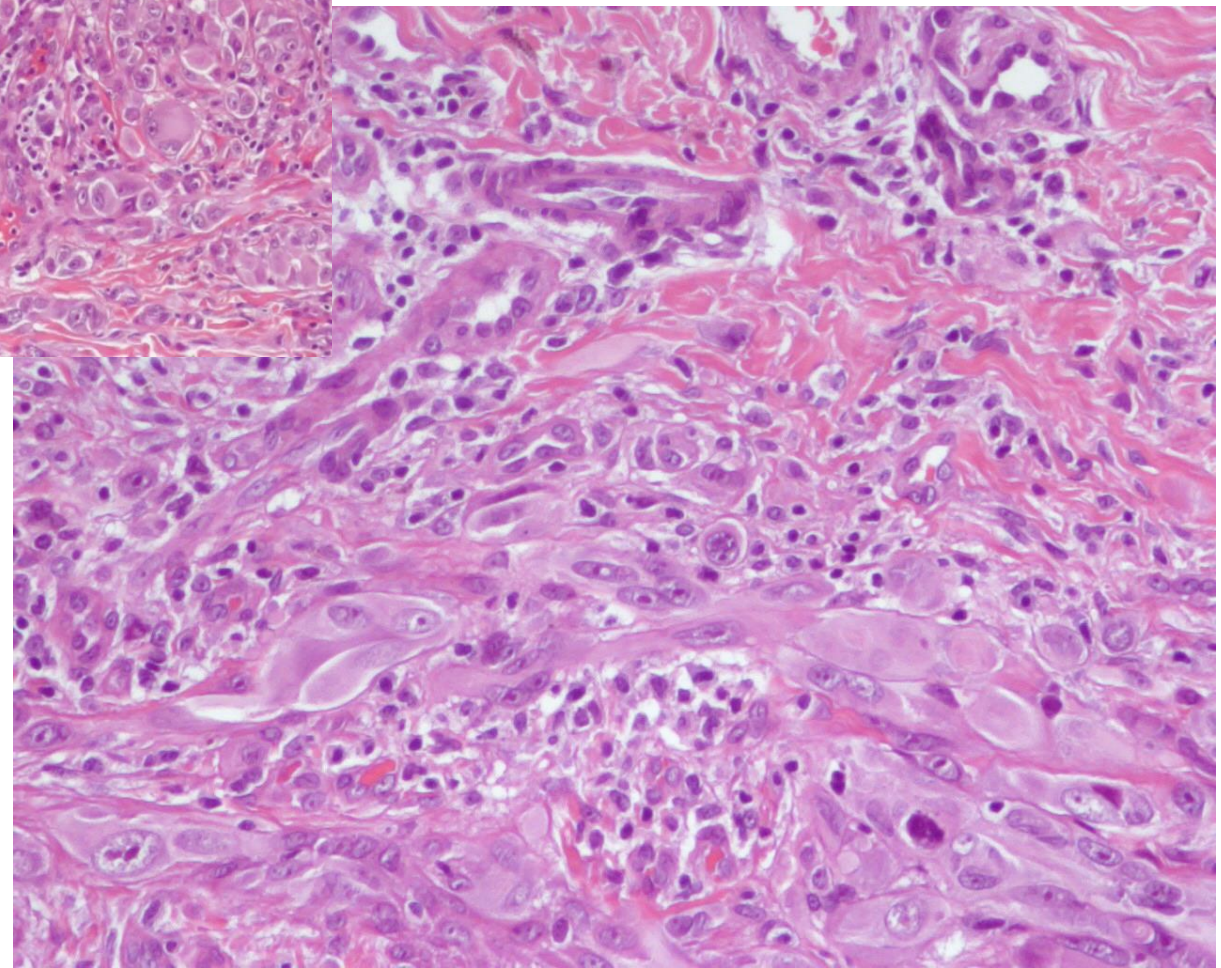

Presenza delle SWS nelle lesioni non-melanocitiche

- Dermatofibromi

- Basaliomi
  - Fibroepitelioma di Pinkus

- Cicatrici
- Granulomi piogenici
- Cheratosi lichenoidi
- …

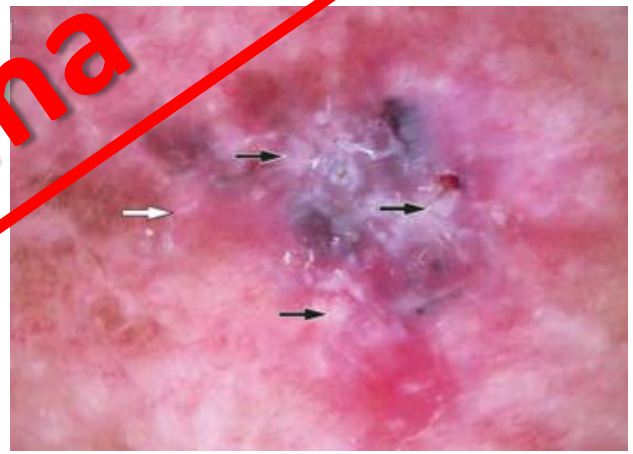

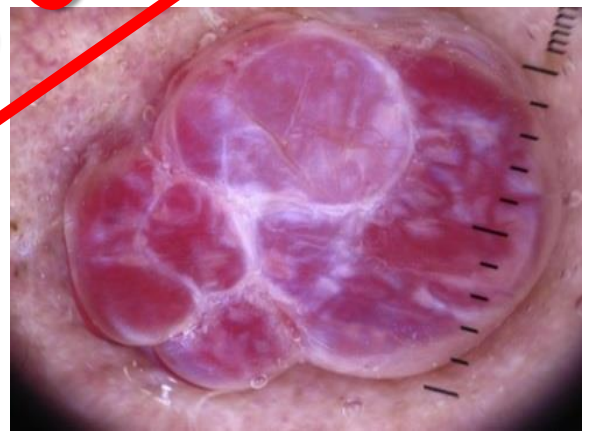

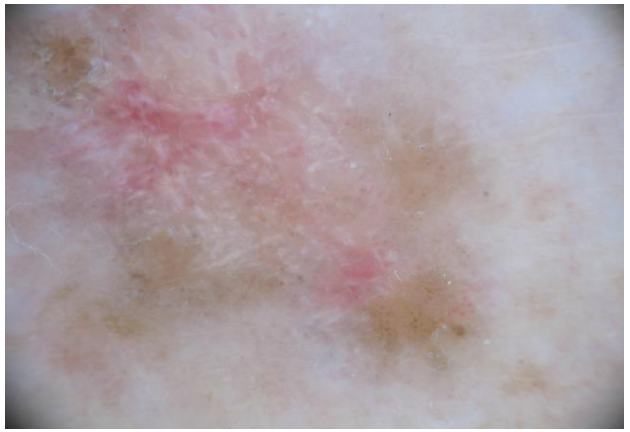

Le SWS non sono un criterio specifico di melanoma

SWS/crisalidi: resumè

- Le SWS non sono un criterio specifico di melanoma
- Ma possono rappresentare un criterio utile nella diagnosi di melanoma (spesso presenti)
- Specie se associate ad altri criteri che depongono per una natura melanocitaria

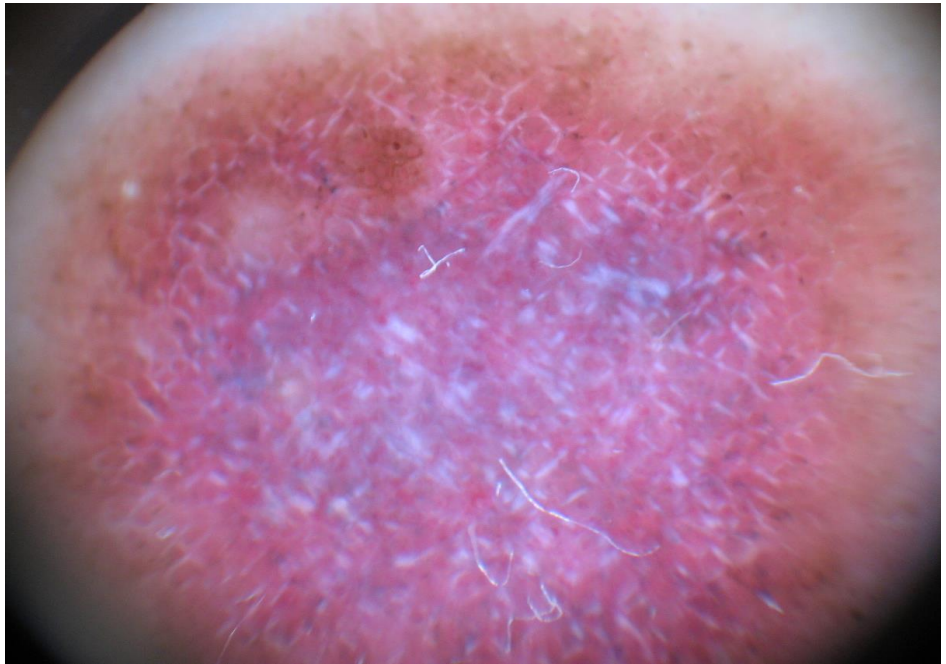

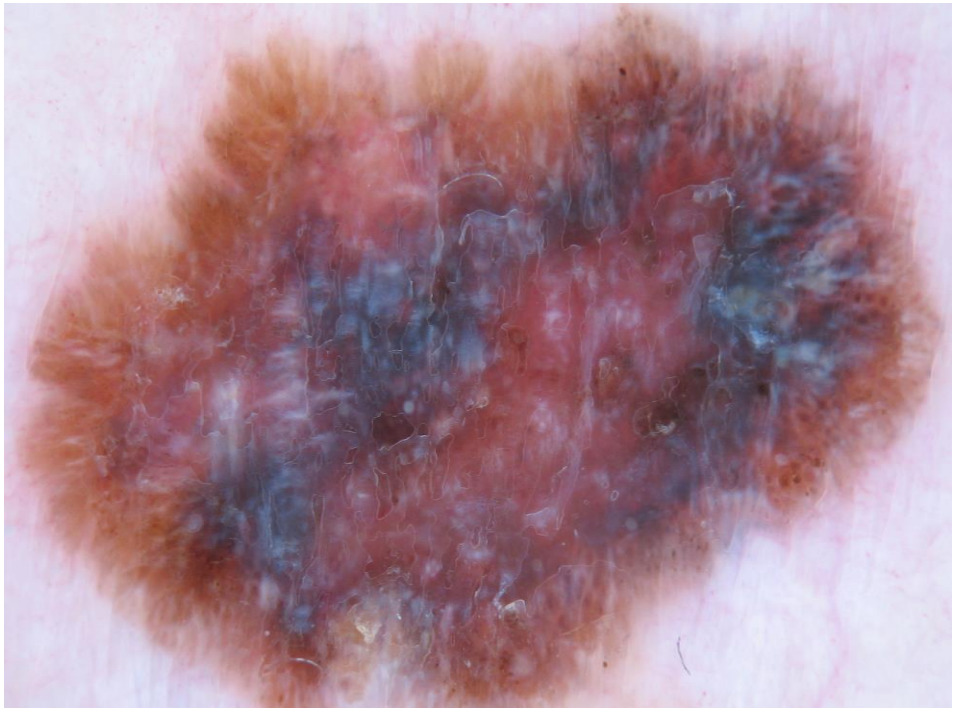

The “blink sign”

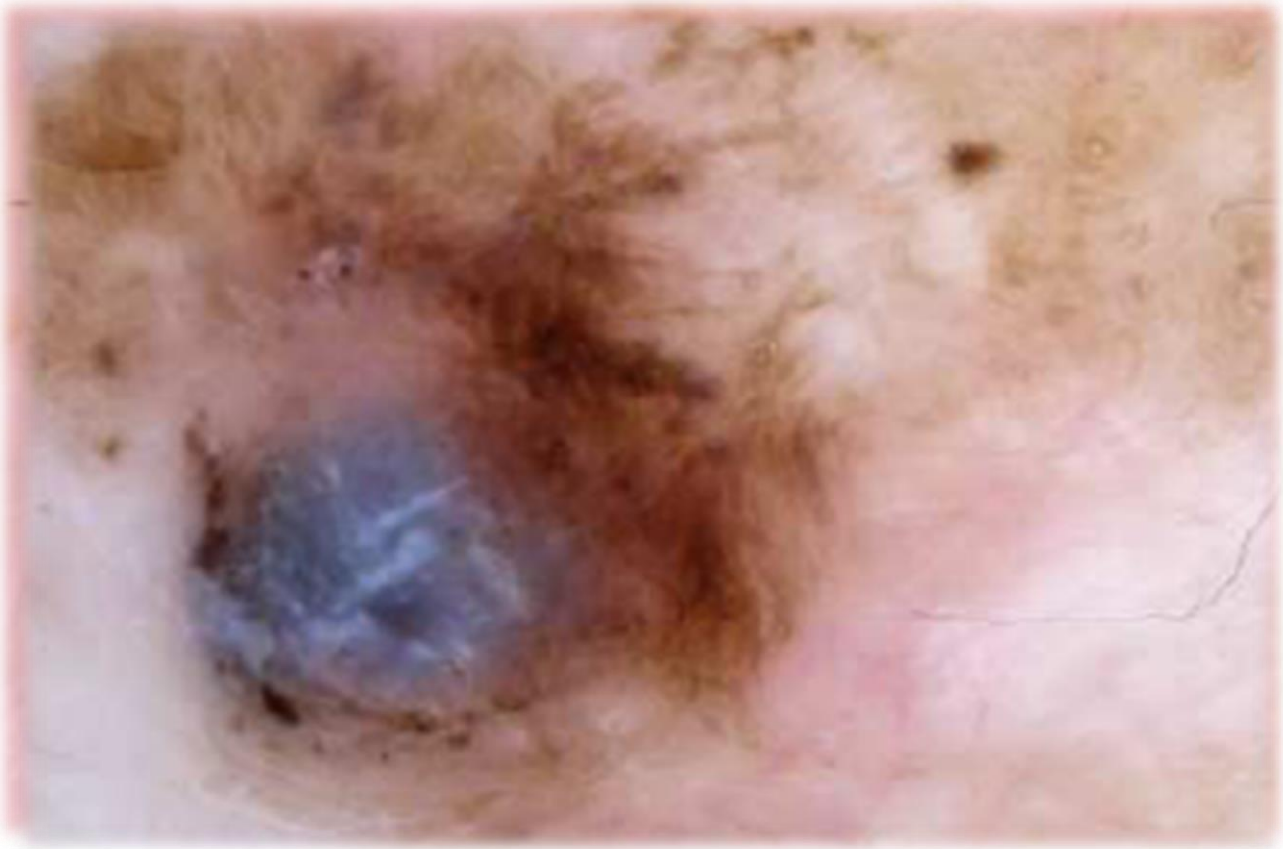

Visibile mediante i dermatoscopi ibridi che permettono di passare dalla modalità a luce non polarizzata alla modalità a luce polarizzata

Braun RP. et al. *Arch Dermatol* 2011;147:520.

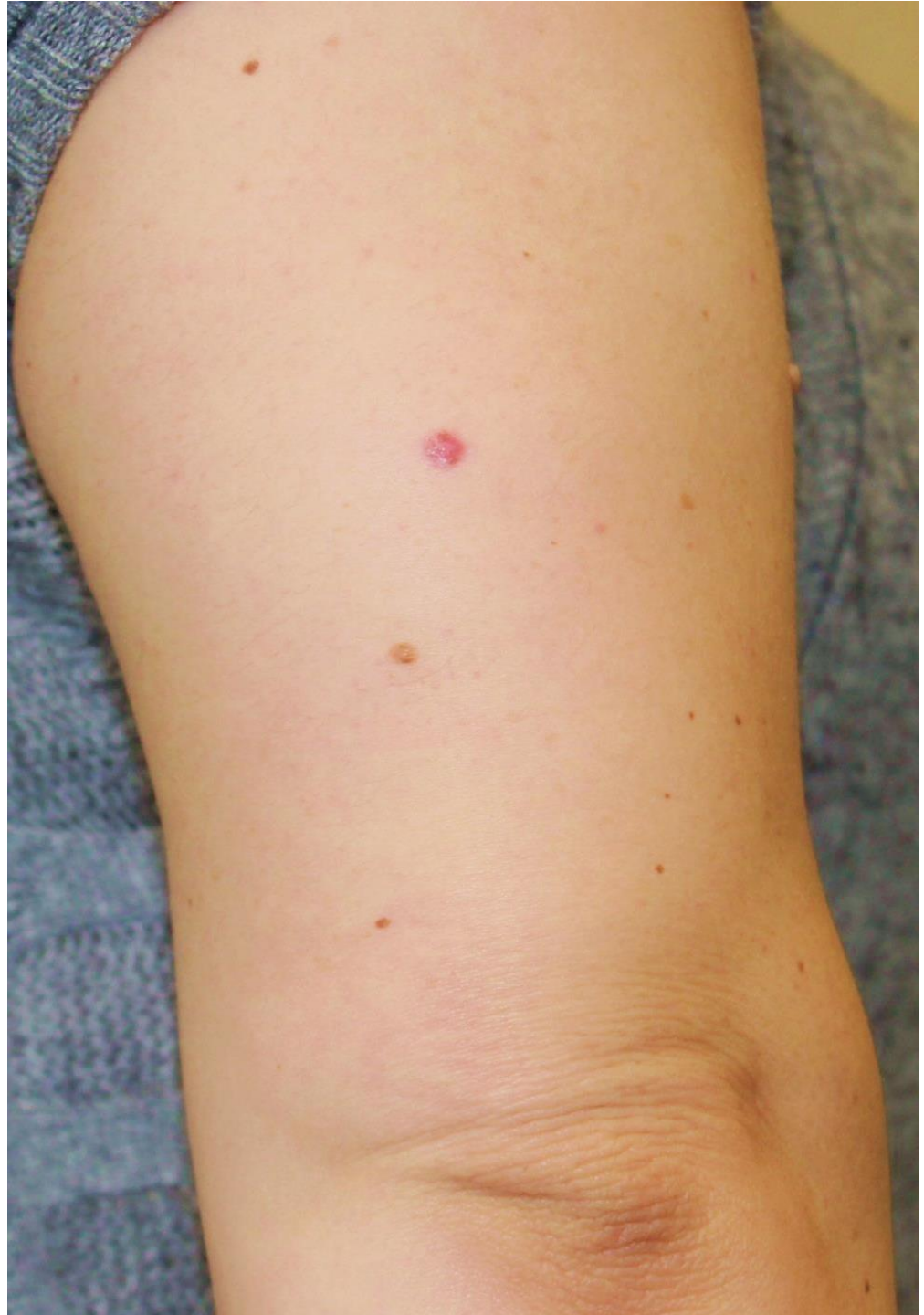

F 37

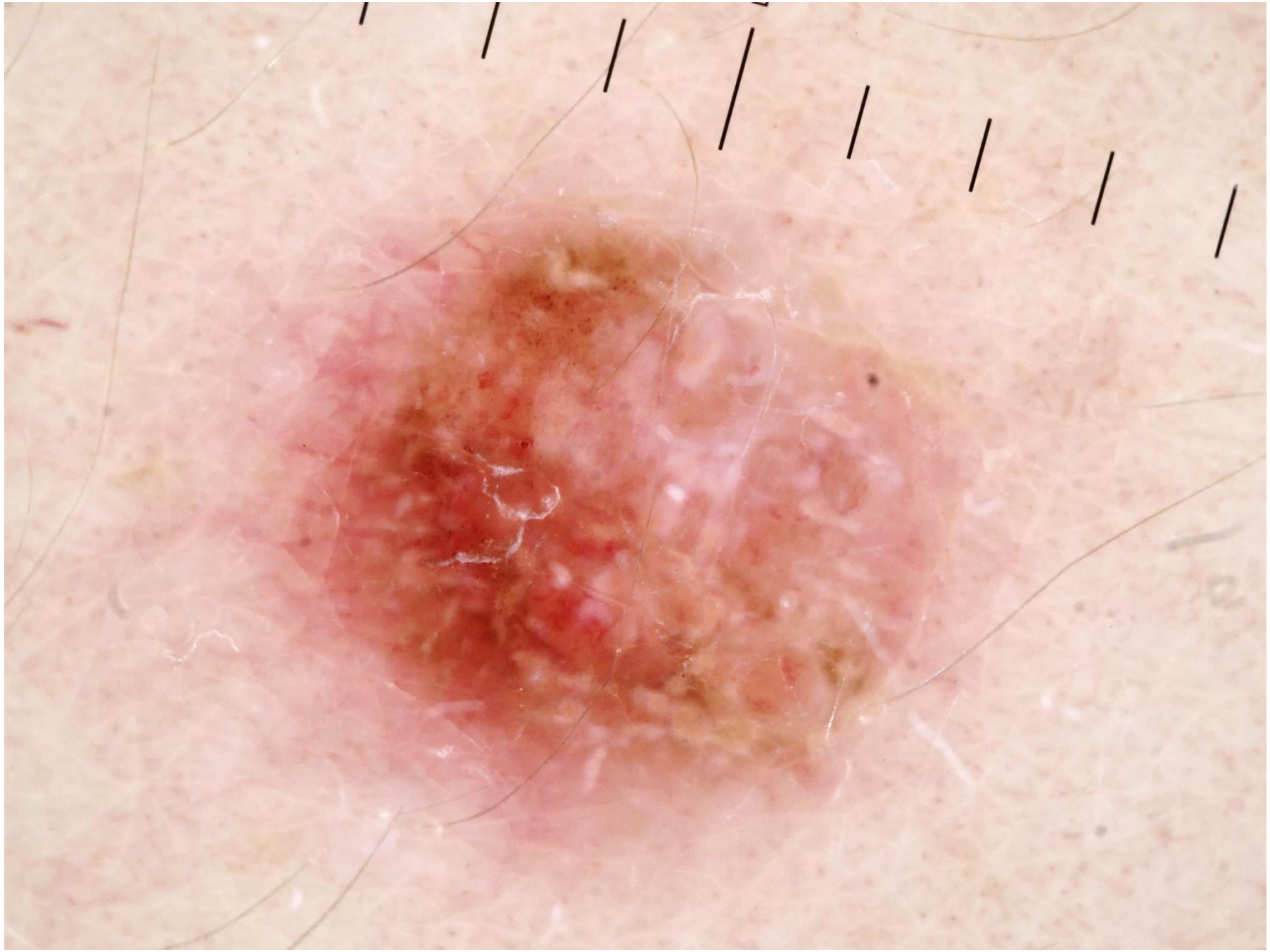

Le SWS non sono le uniche strutture biancastre identificabili con la dermoscopia

White shiny structures: dermoscopic features revealed under polarized light

T.N. Liebman,[†] H.S. Rabinovitz,[‡] S.W. Dusza,[†] A.A. Marghoob[†,*]

Rosettes

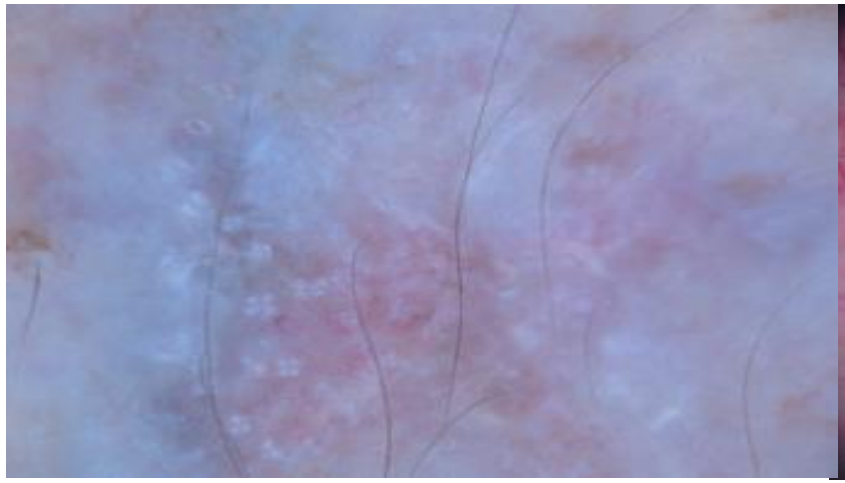

AK/SCC

White-shiny areas

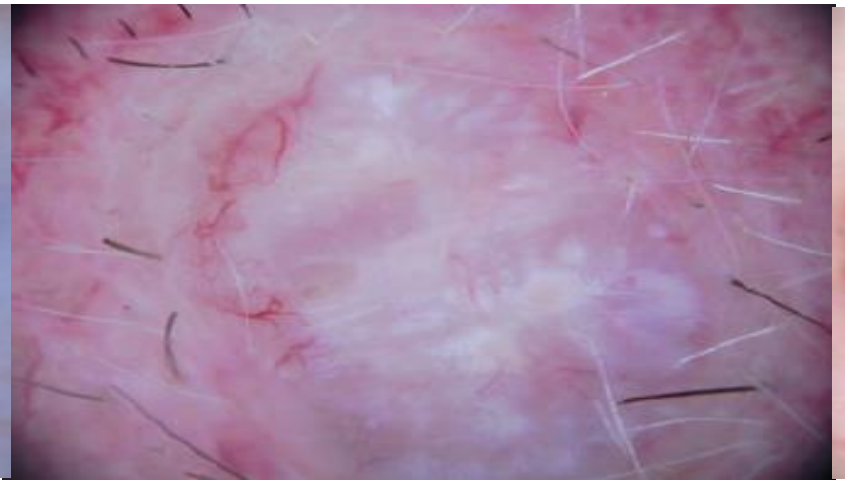

BCC

SWS o Crystalline structures

Melanoma

Liebman TN. et al. *J Eu Acad Dermatol Venereol* 2012;26:1493-7.

White-shiny areas

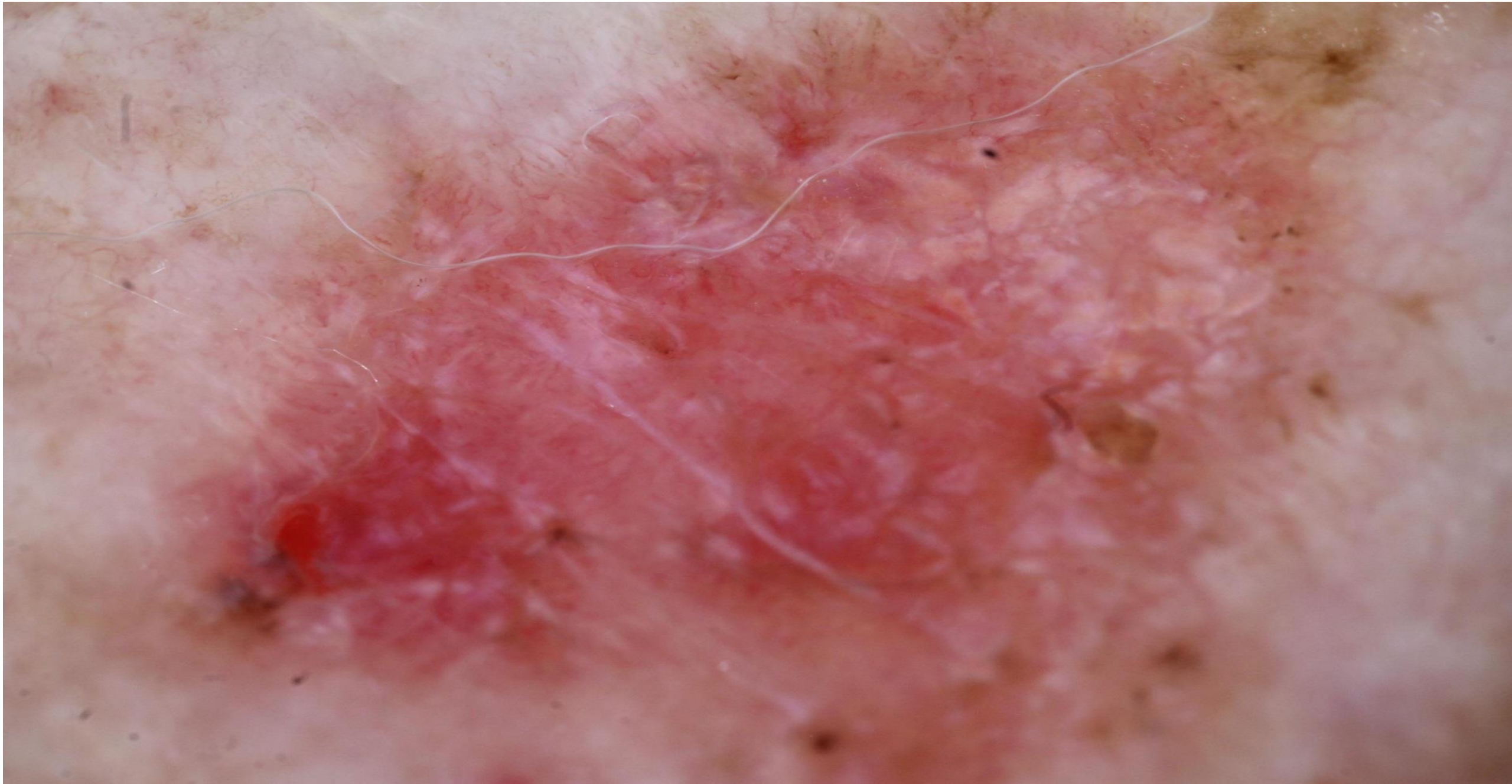

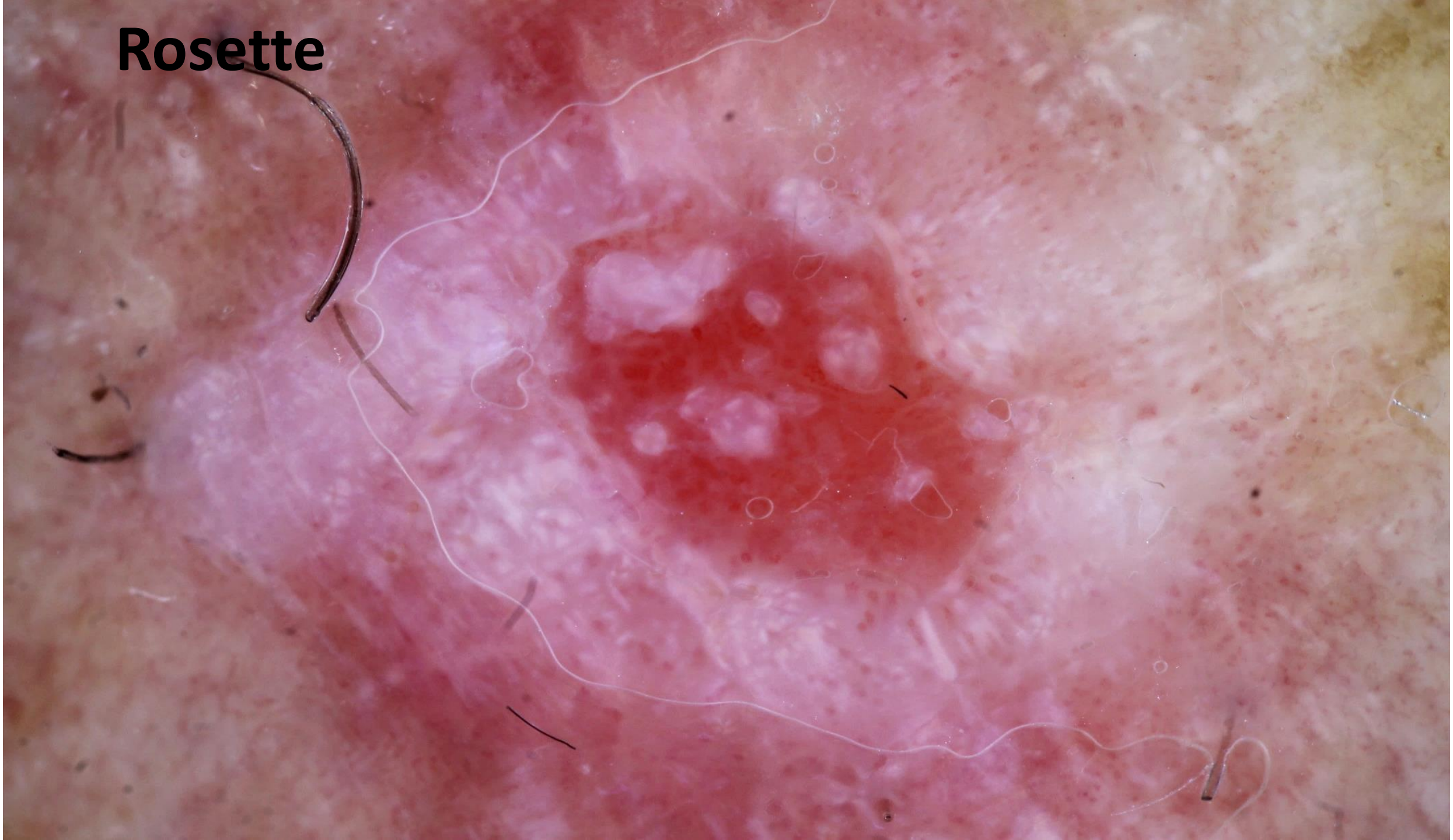
Rosette

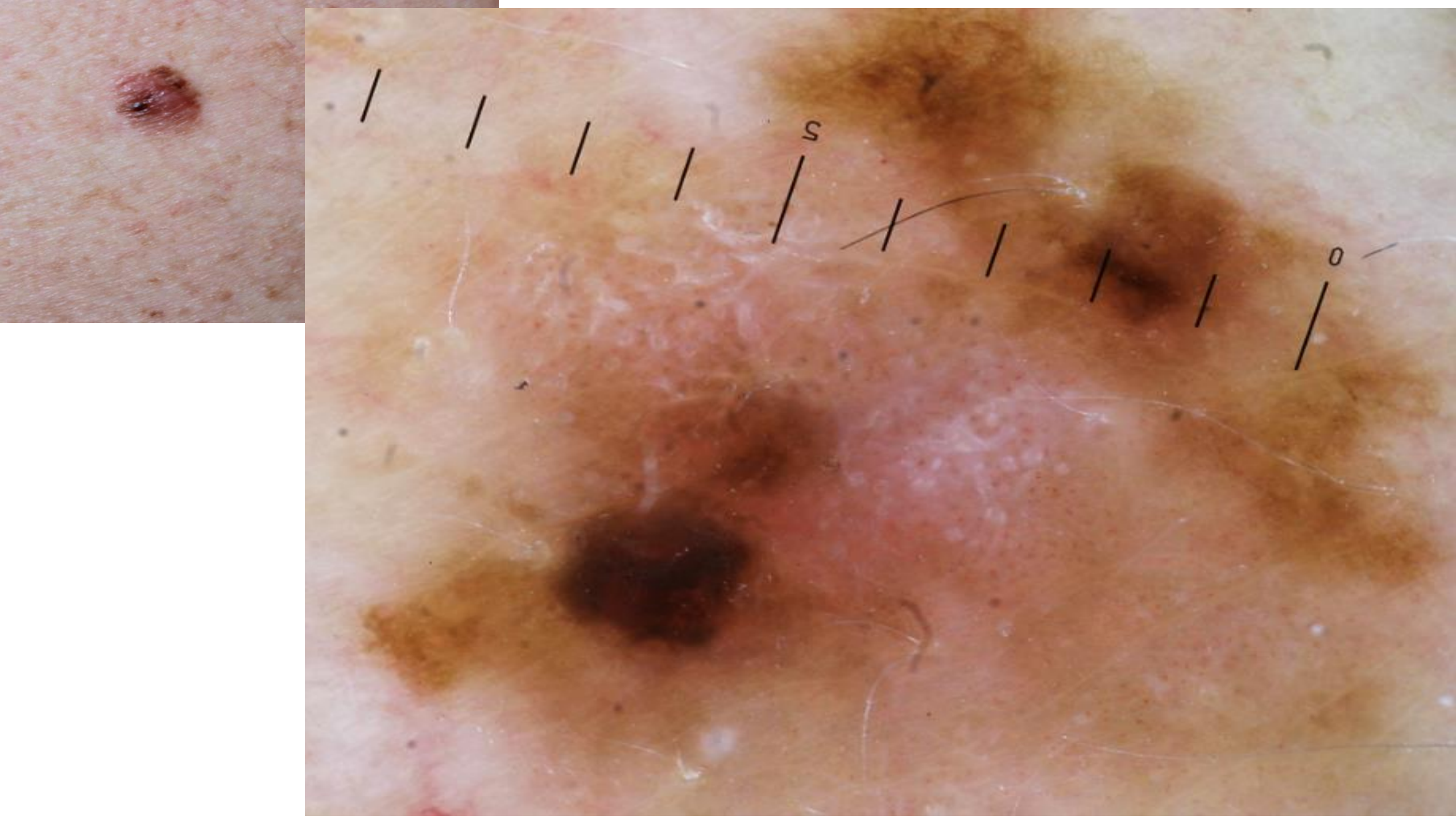

Pink / featureless lesions

1. *Pattern Vascolari*
2. *Criteri per diagnosi specifiche*
3. *Residui di pigmento*
4. *Pattern a luce polarizzata*
5. *Clinica*

Amelanotic Melanoma

ABCD is often negative

EFG rule:

- **E**: Elevated
- **F**: Firm to palpation
- **G**: Growing continuous over 1 month

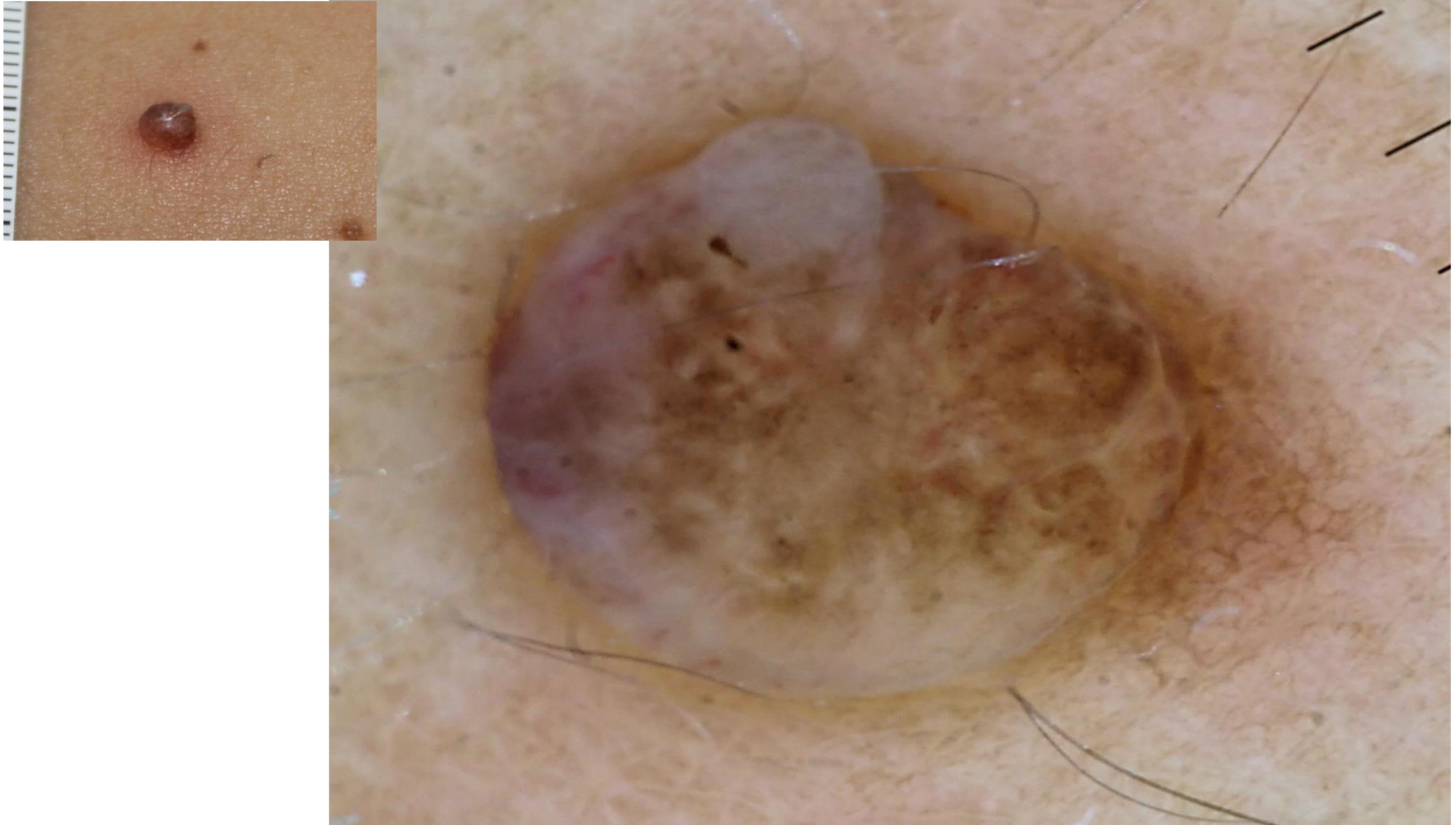

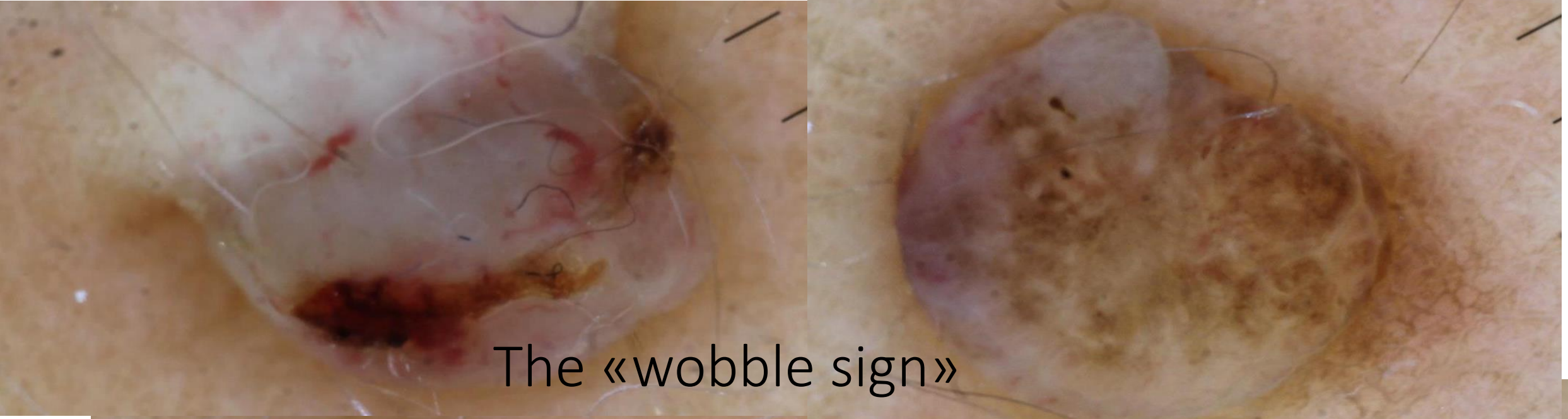

The «wobble sign»

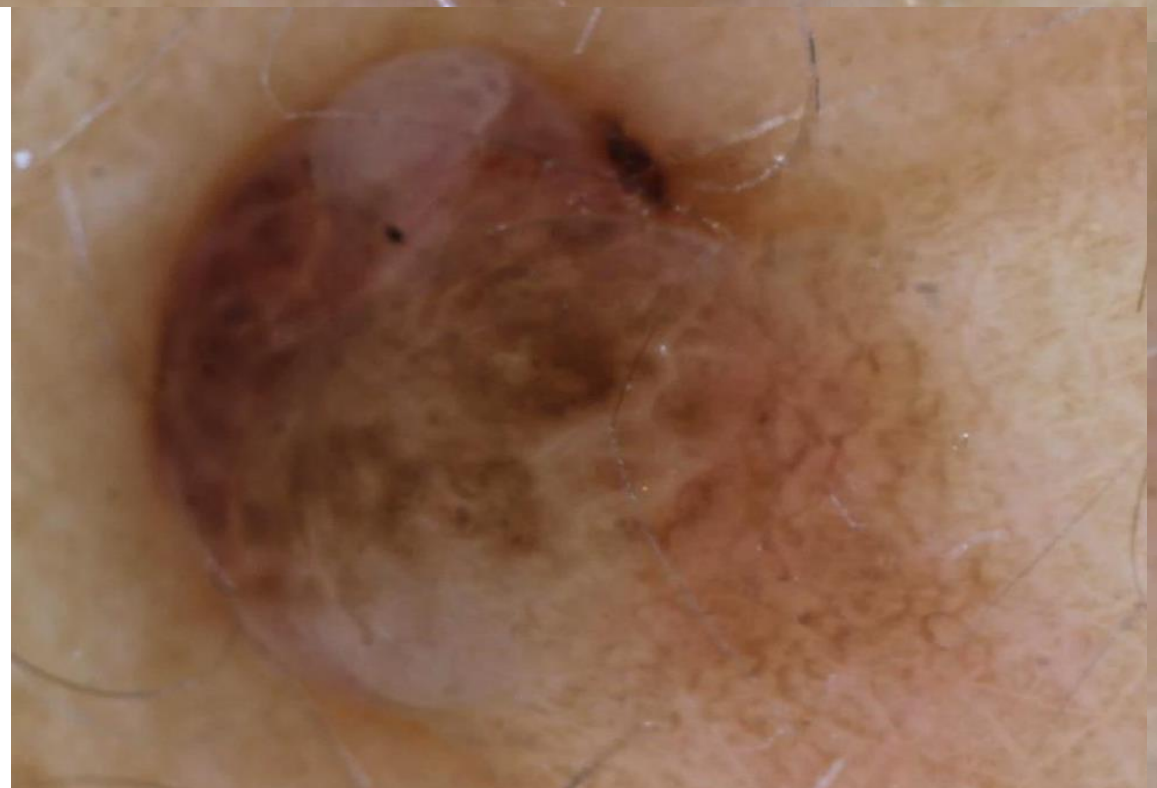

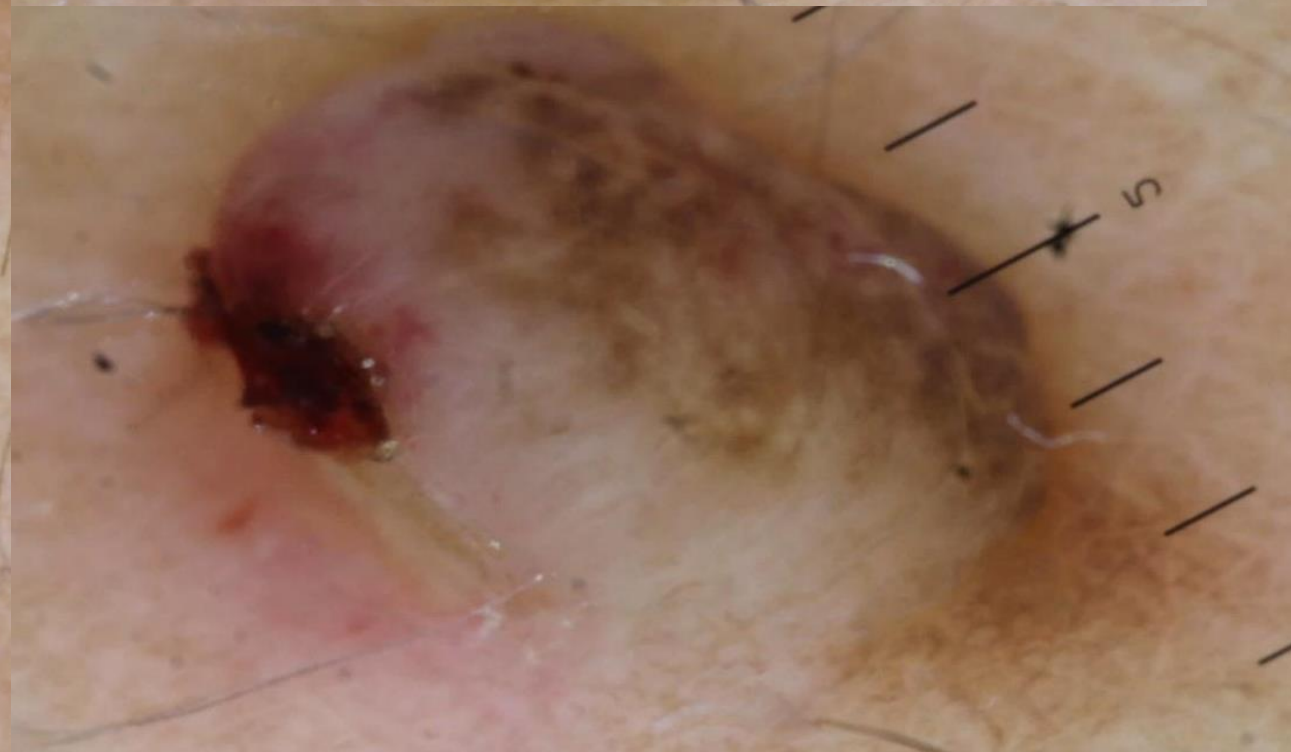

Assenza di corrispondenza tra clinica e dermoscopia

Lesione che rivela un pattern dermoscopico discordante con la clinica o inatteso

Zalaudek I, Ferrara G, Di Stefani A et al.
Br J Dermatol. 2005;153:200-202.

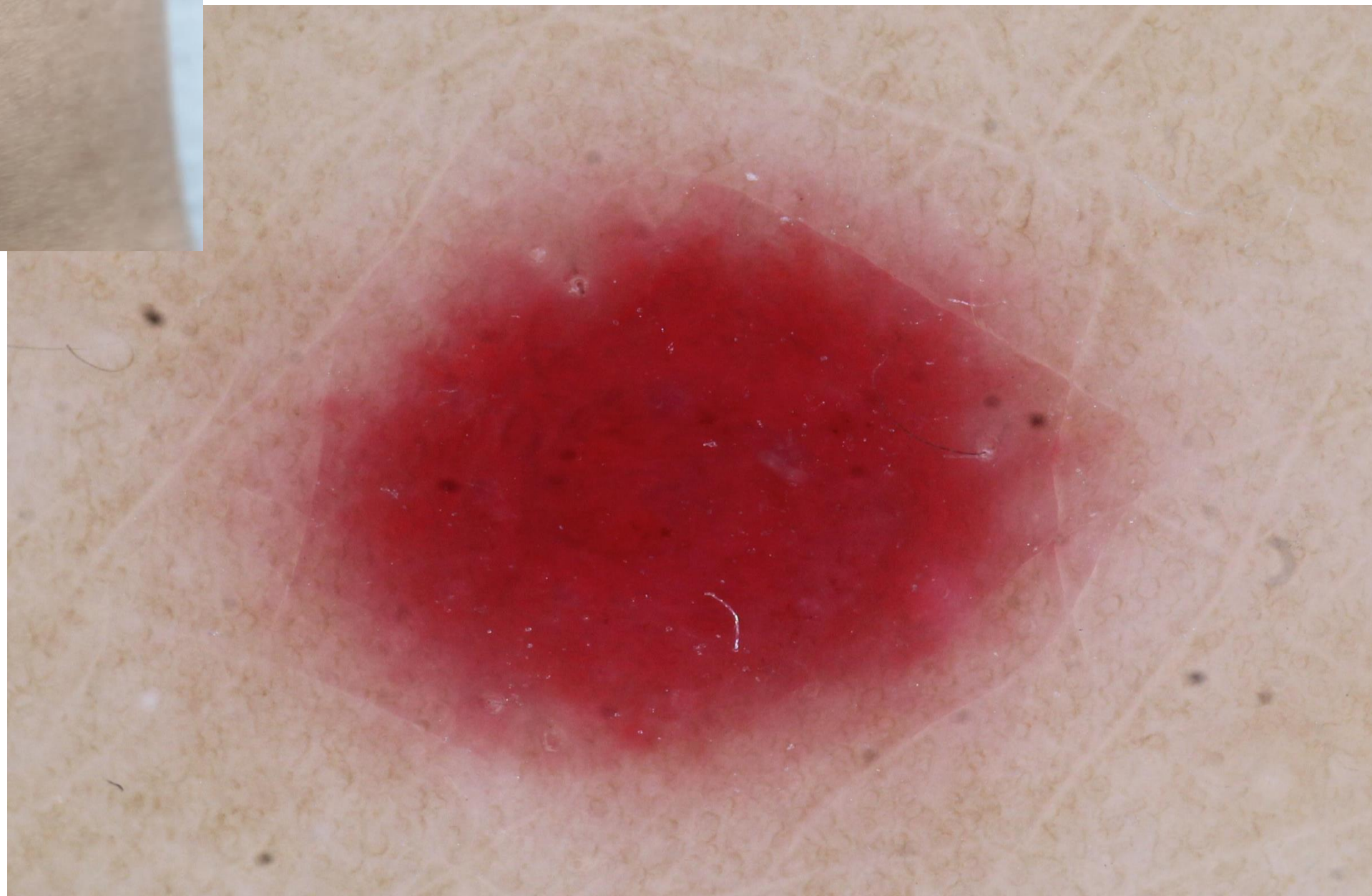

Ci si sceglie
a farselo un po'
in campagnia...
questo viaggio in cui
non si ripassa dal via

PREDICTION without PIGMENT

A Decision Algorithm for Non-Pigmented Skin Malignancy

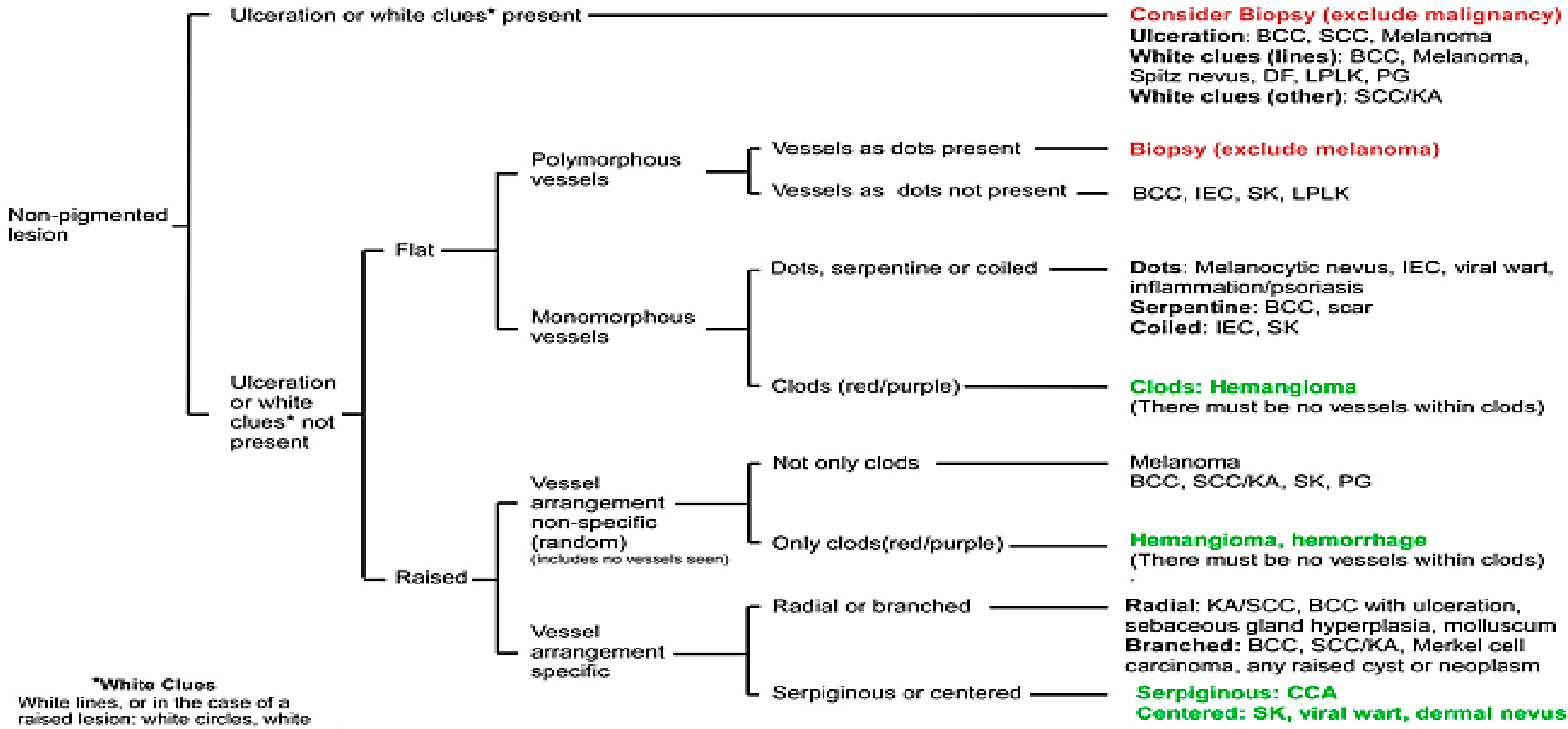

***White Clues**
White lines, or in the case of a raised lesion: white circles, white structureless areas or surface keratin.

Take home messages

- Asportare ogni lesione pink che non può essere diagnosticata con confidenza come benigna dopo accurato esame clinico-dermoscopico
- Soprattutto se:
  - pattern dermoscopico aspecifico + vasi irregolari e/o ulcerazione
  - lesioni amelanotiche solitarie che mostrano un pattern dermoscopico discordante o inatteso

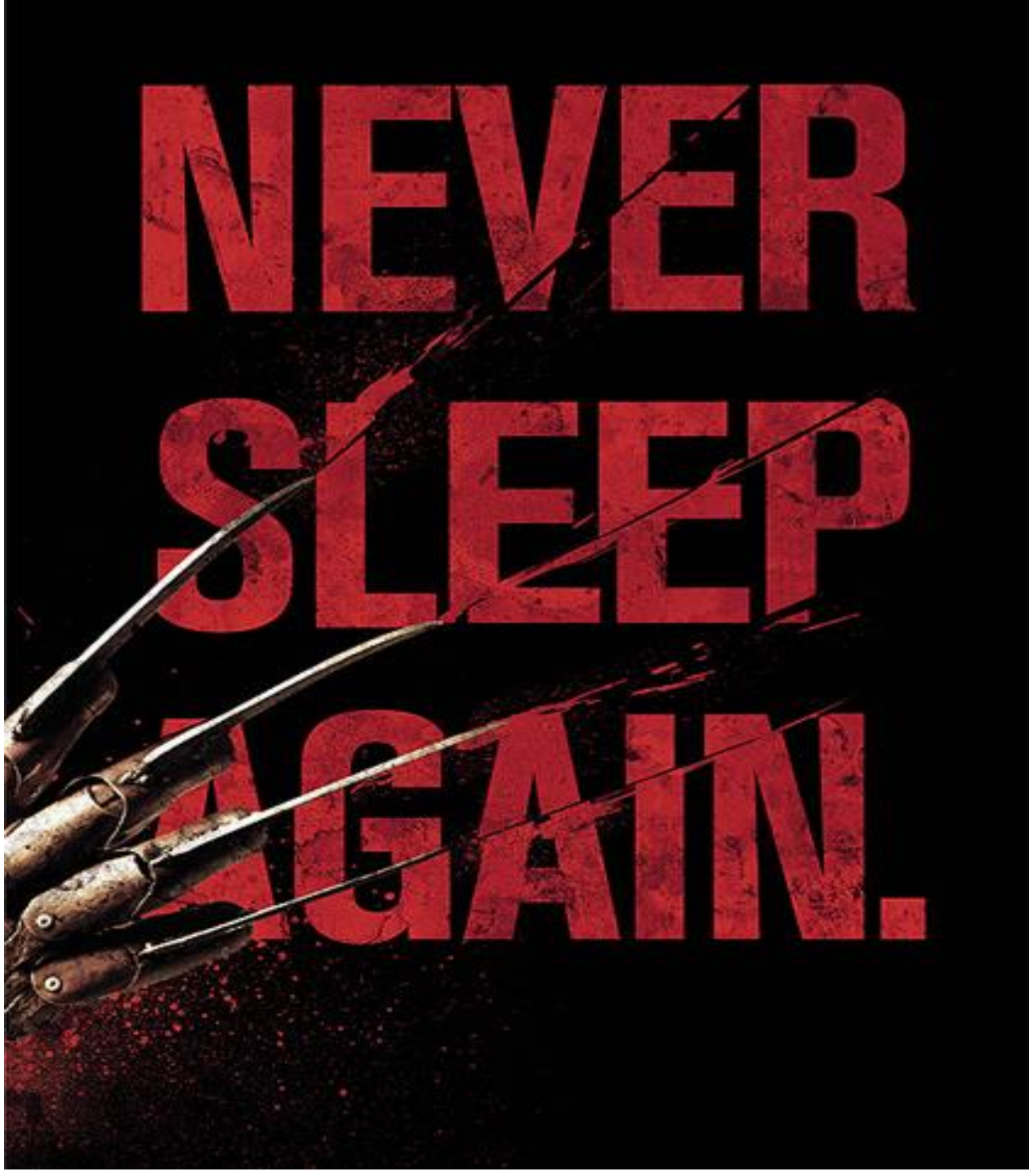
NEVER
SLEEP
AGAIN.


HE KNOWS WHERE YOU SLEEP.
A NIGHTMARE
ON ELM STREET